Clinical Pathological Case (CPC)

Seed
GLOBAL HEALTH

CPC
CASE-BASED LEARNING SERIES
"Mastering Emergency Care"

Disclaimer

Clinical Pathological Case training videos are for educational purposes and should not be used as the sole source of reference during patient care. Always refer to official guidelines and consult qualified professionals before applying any practices

Case Based Learning Series
“Student Led Adult Learning”

CPC
CASE-BASED LEARNING SERIES
"Mastering clinical Reasoning in Emergency Medicine"

Seed
GLOBAL HEALTH

Clinical Pathologic Case (CPC)

Emergency Medicine Case Based Series



THEME:

He was vomiting blood

Date: 26TH JUN 2026 | **Time:** 7:00 PM - 8:00 PM

Expert



Dr. Emuron Joseph
EM Physician (expert)

Case Presenter



Jasper Obale
MBChB V Gulu University

Prehospital Presenter



Aryatemba Durf
Diploma Emergency Care student

zoom
SCAN QR CODE TO REGISTER
https://shorturl.at/JHmc5

FUMSA
DELTA EM
MAKERERE EMERGENCY MEDICINE INTEREST GROUP

Presenting Complaint

51/M Vomiting blood x1/7



ISBAR Handover

Introduction: DURF ARYATEMBA, an EMT from Lubaga training school handing over 51yr/M patient.

Situation: **D**izzy & vomited blood 500mls of bright red blood

Background: Chronic epigastric pain, No alcohol or NSAID. On omeprazole 40mg for 4 days.

Assessment: Patent airway, 24breaths/min, 93% SPO2 on 2L Oxygen, Pulse120 bpm , BP 90/60 mmHg with pale, cool and clammy Skin, GCS 15/15

Concerning for hypovolemic shock

Recommend: Further work up and EM physician / gastroenterologist evaluation, blood , fluids

Poll 1

What are the key pre-hospital interventions for this patient?

Pre-hospital Management

- Suctioning performed
- Oxygen 2L by nasal cannula
- Two large-bore IV lines
- Crystalloid fluid initiated
- Continuous monitoring during transport.

Primary Survey

Airway: Patent. Fully conscious

Breathing: RR 21/min, SpO_2 90% RA, equal air entry

Circulation: Weak, low volume pulse and regular , tachycardia of 120 bpm, BP 98/62 mmHg, CRF<2s

Disability: GCS 15/15, pupils equal and reactive, RBS 3.1mmol/L

Exposure : Cold (36.4C) Very pale, pitting edema, No bleeding

SAMPLE History

Signs & Symptoms: **vomiting blood** 2 episodes, constipation, Epigastric pain, loss of appetite, Headache, dizziness & blurred vision

Allergies: None

Medications: Omeprazole 40mg OD for 4 days

Past Medical History**:** Unremarkable. ***Severe anemia*** at lower facility, got *several units of blood*.

Last Meal: 36 hrs

Events leading to Presentation: as above

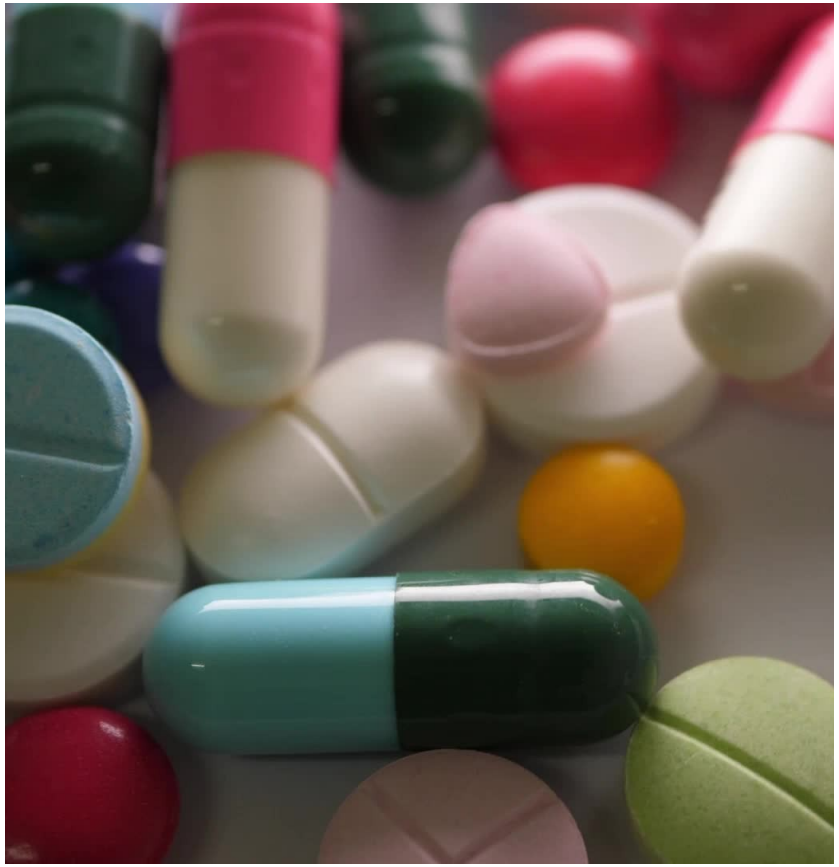

Poll 2

From the primary & secondary survey what are the emergencies in this patient?



Audience

Any additional information?

Expert



What are your initial thoughts?



What is you preparation and approach to this patient?

Poll 3

What are the emergency interventions for this patient?

ED Intervention

- **Airway:** Recovery position
- **Breathing:** 10L Oxygen via non-rebreather mask with continuosly monitoring
- **Circulation**: CBC, U&E, LFTs, coagulation profile and cross-match, N/S, omeprazole 80 mg IV bolus then 8 mg/hr infusion
- **Disability:** 50mls of Dextrose 50%. Neuro observations continued
- **Exposure:** Kept warm ,Temperature monitored

Secondary survey

- Head and Neck: **Severe conjunctival pallor,** No signs of trauma
- Chest: Normal
- Abdomen/rectal: Soft, non-distended, **Mild epigastric tenderness**, No guarding or rebound tenderness, No organomegaly, Bowel sounds 3/min. **Black tarry stool**, no fresh blood or rectal masses

- **Extremities**: Grade II bilateral pitting oedema. **Cold peripheries**. Cap refill <2 seconds.

- **Neurological:** GCS 15/15. No neurological deficits

- **Skin:** No signs of trauma, spider naevi.

Expert opinion?



Any additional thoughts at this point?



Any additional info you would want to get?

PROBLEM LIST

- Hypovolemic Shock
- Severe Anemia
- Hypoxemia (SpO_2 90%)
- Hypoglycemia (RBS 3.1)
- Grade II Bilateral Pedal Edema
- Epigastric Pain

Poll 4

What are the key bedside investigations for this patient?

Investigations

CBC

Blood group and cross match

HIV

Hep B&C

U&E

LFTs

Abdominal US

Coagulation profile

Endoscopy

Hpylori

Lab results

Gender: Male
Age: 51Years

Test time: 05/06/2026 18:25:23
Print time: 05/06/2026 18:25:23

	Parameters		Result	Unit	Ref. range
1	**WBC**	**H**	**16.63**	**10^9/L**	**3.50-9.50**
2	Neu%		66.9	%	40.0-75.0
3	Lym%		29.2	%	20.0-50.0
4	Mon%		3.3	%	3.0-10.0
5	Eos%	L	0.1	%	0.4-8.0
6	Bas%		0.5	%	0.0-1.0
7	Neu#	H	11.13	10^9/L	1.80-6.30
8	Lym#	H	4.86	10^9/L	1.10-3.20
9	Mon#		0.54	10^9/L	0.10-0.60
10	Eos#		0.02	10^9/L	0.02-0.52
11	Bas#	H	0.08	10^9/L	0.00-0.06
12	IG%		1.1	%	
13	IG#		0.18	10^9/L	
14	**RBC**	**L**	**2.39**	**10^12/L**	**4.30-5.80**
15	**HGB**	**L**	**5.8**	**g/dL**	**13.0-17.5**
16	HCT	L	0.191		0.400-0.500
17	MCV	L	79.9	fL	82.0-100.0
18	MCH	L	24.1	pg	27.0-34.0
19	MCHC	L	30.2	g/dL	31.6-35.4
20	RDW-CV	H	18.1	%	11.0-16.0
21	RDW-SD		50.4	fL	35.0-56.0
22	**PLT**	**H**	**631**	**10^9/L**	**125-350**
23	MPV		8.5	fL	6.5-12.0
24	PDW		10.8	fL	9.0-17.0
25	P-LCR		15.5	%	11.0-45.0
26	P-LCC	H	98	10^9/L	30-90
27	**PCT**	**H**	**0.537**	**%**	**0.108-0.282**

Flag Info

Neutrophilia
Lymphocytosis
Abn Lympho/ Blasts?
Reactive Lympho?
Immature Gran?

Anemia

Thrombocytosis

WBC/BASO



RBC

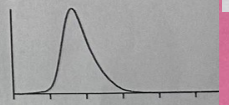

PLT

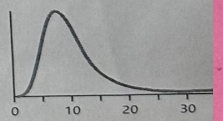

BFS for mps — No mps seen

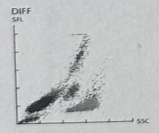

Analysed by: 5/6/26

Reviewed & Approved by:

3	Lym%		29.2	%	20.0-50.0
4	Mon%		3.3	%	3.0-10.0
5	Eos%	L	0.1	%	0.4-8.0
6	Bas%		0.5	%	0.0-1.0
7	Neu#	H	11.13	10^9/L	1.80-6.30
8	Lym#	H	4.86	10^9/L	1.10-3.20
9	Mon#		0.54	10^9/L	0.10-0.60
10	Eos#		0.02	10^9/L	0.02-0.52
11	Bas#	H	0.08	10^9/L	0.00-0.06
12	IG%		1.1	%	
13	IG#		0.18	10^9/L	
14	**RBC**	**L**	**2.39**	**10^12/L**	**4.30-5.80**
15	**HGB**	**L**	**5.8**	**g/dL**	**13.0-17.5**
16	HCT	L	0.191		0.400-0.500
17	MCV	L	79.9	fL	82.0-100.0
18	MCH	L	24.1	pg	27.0-34.0
19	MCHC	L	30.2	g/dL	31.6-35.4
20	RDW-CV	H	18.1	%	11.0-16.0
21	RDW-SD		50.4	fL	35.0-56.0
22	**PLT**	**H**	**631**	**10^9/L**	**125-350**
23	MPV		8.5	fL	6.5-12.0
24	PDW		10.8	fL	9.0-17.0
25	P-LCR		15.5	%	11.0-45.0
26	P-LCC	H	98	10^9/L	30-90
27	**PCT**	**H**	**0.537**	**%**	**0.108-0.282**

Lymphocytosis
Abn Lympho/ Blasts?
Reactive Lympho?
Immature Gran?

Anemia

Thrombocytosis

WBC/BASO



RBC

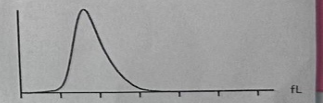

PLT

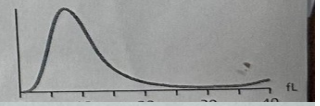

BFS for mps — No mps seen

Chemistry	Result	Unit	Flag	Ref R
T-Bil	0.5	mg/dL		0.0-1
D-Bil	0.3	mg/dL	H	0.0-0
ALT	38	U/L		0-40
AST	45	U/L	H	0-37
ALP	38	U/L	L	98-2
ALB	2.3	g/dL	L	3.8-5
CREA	1.1	mg/dL		0.1-1
UREA	44	mg/dL		10-5
AST/ALT	1.2			
IBIL	4.85	µmol/L		
TP	2.7	g/dL	L	6.6-

Investigations	Results
CBC	WBC 16.3 Hb 5.8g/dl: microcytic hypochromic anemia PLT 631x10*9
LFTs	Mild Direct Bil , AST elevation (<x2)
Abdominal Ultrasound	Normal
Malaria, HIV, Hepatitis Band C	Negative

Differentials

- Erosive Gastritis
- Bleeding peptic ulcer disease
- Esophageal varices, ectopic varices, Bleeding gastric carcinoma
- Vascular lesions; Dieulafoy's lesion, angiodysplasia
- Mallory-Weiss tear

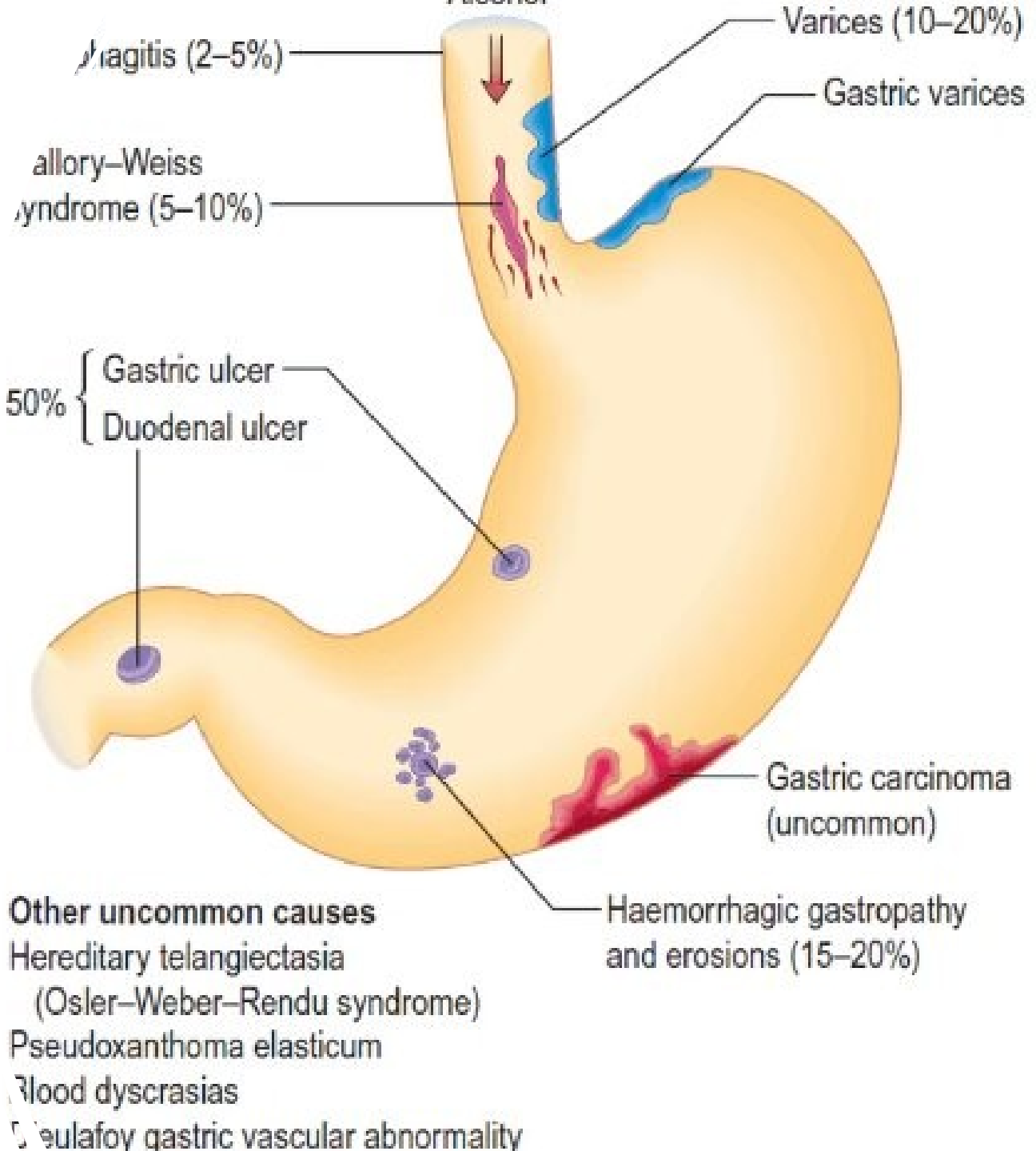

Working diagnosis

Upper gastrointestinal bleeding secondary to PUD, complicated to severe anemia

Expert opinion



What are your differentials at this point



What is your management plan?

Hospital course

Admission



ADMITTED TO THE MEDICAL WARD



IV OMEPRAZOLE, CEFTRIAXONE 1G OD & METRONIDAZOLE 500MG 8HRLY



SUPPORTIVE: IV DEXTROSE, OXYGEN , 1 UNIT OF PRBCS



NIL BY MOUTH FOR ENDOSCOPY.



SERIAL VITAL SIGNS AND HEMOGLOBIN

Plan

- Serial monitoring
- Upper gastrointestinal endoscopy
-
- Helicobacter pylori test +/- treat
-
- Continue PPIs

Expert

Pearls and pitfalls

Take Home Points.

- Upper GI bleeding is an emergency.
- Early recognition and risk stratification
- prompt ABC resuscitation
- Upper GI endoscopy within 24 hours is essential for diagnosis and definitive management.
- PUD commonest cause, test for and eradicate *Helicobacter pylori*.
- *Ceftriaxone has the highest morbidity benefit in cirrhosis / variceal bleeding*
- Patient education and appropriate follow-up.