

MANAGEMENT OF PAEDIATRIC BOWEL OBSTRUCTION

NIMANYA STELLA ALICE

General Principles

Congenital vs Acquired

Age

Sex

Inflammatory vs Obstructive vs Mass effect

Preoperatively



Is the patient stable or do they need resuscitation?



Which imaging modality is better suited for the patient?



What does the hematological picture look like?

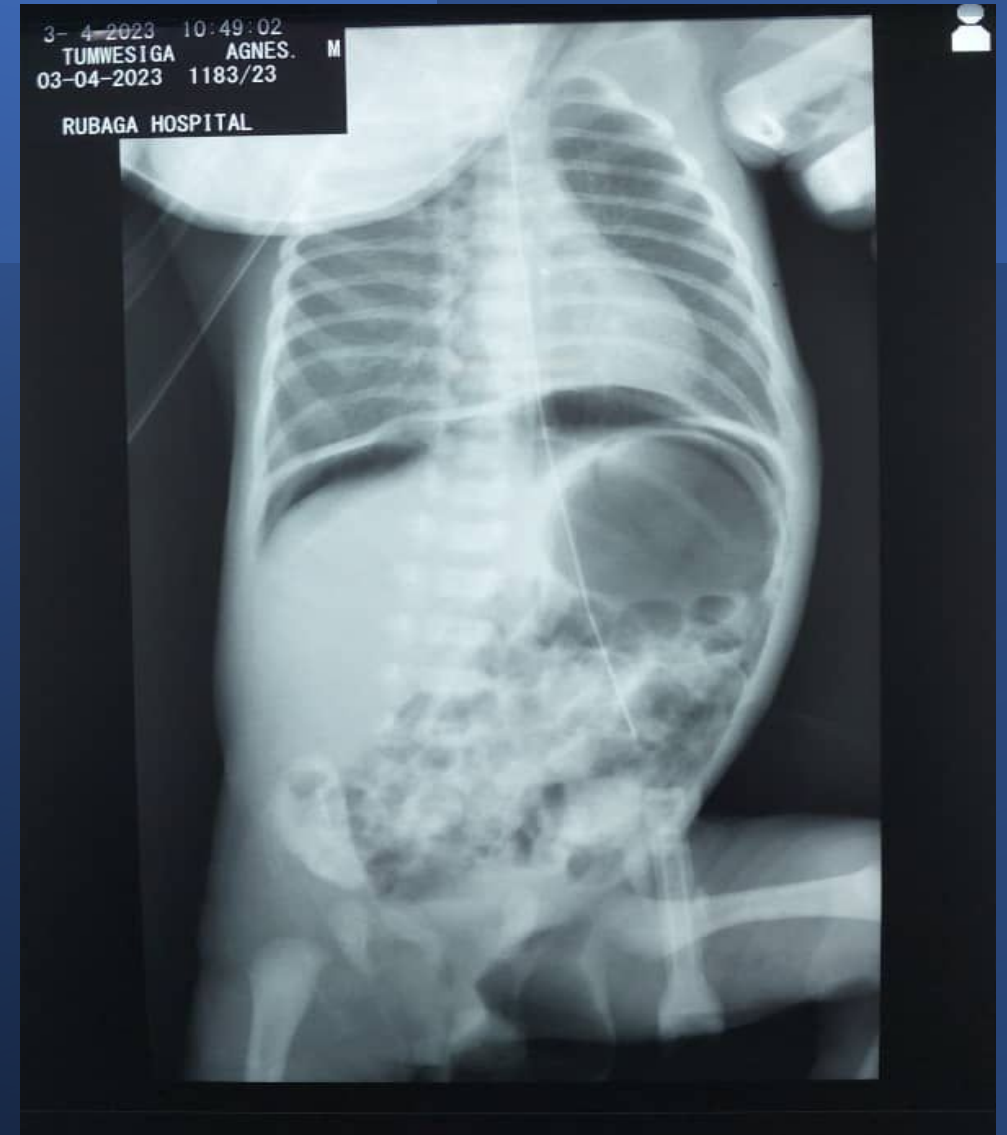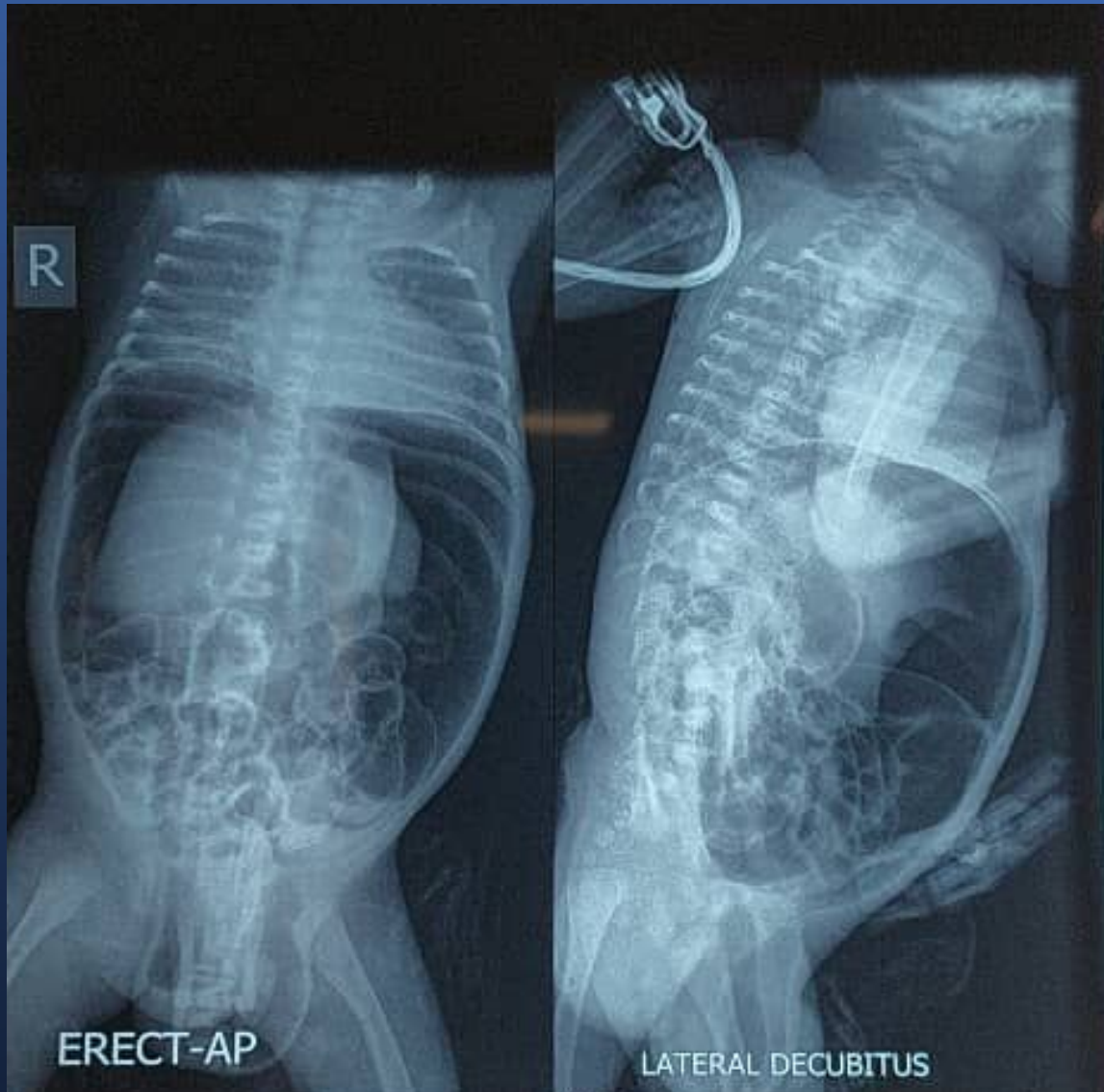Preoperatively



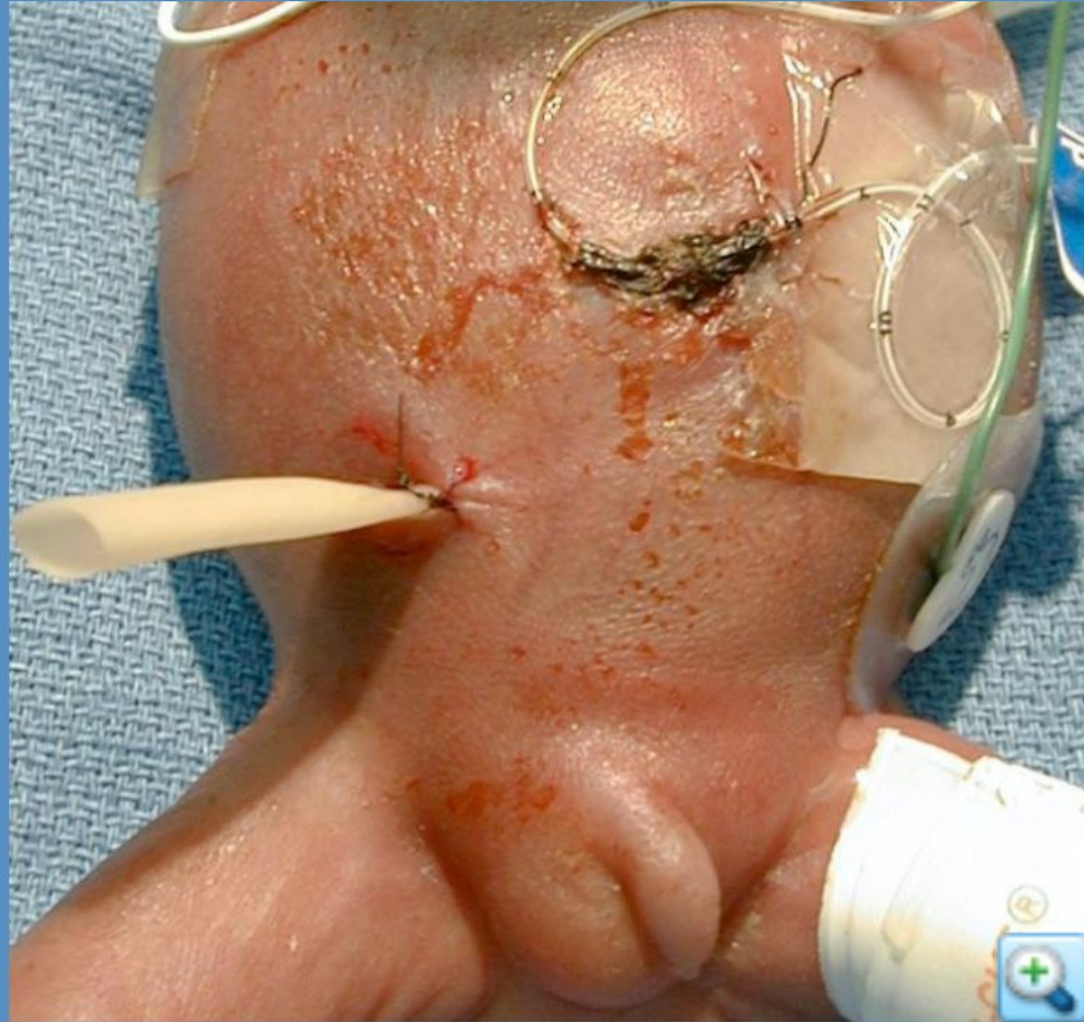
Does the patient “actually” need surgery?

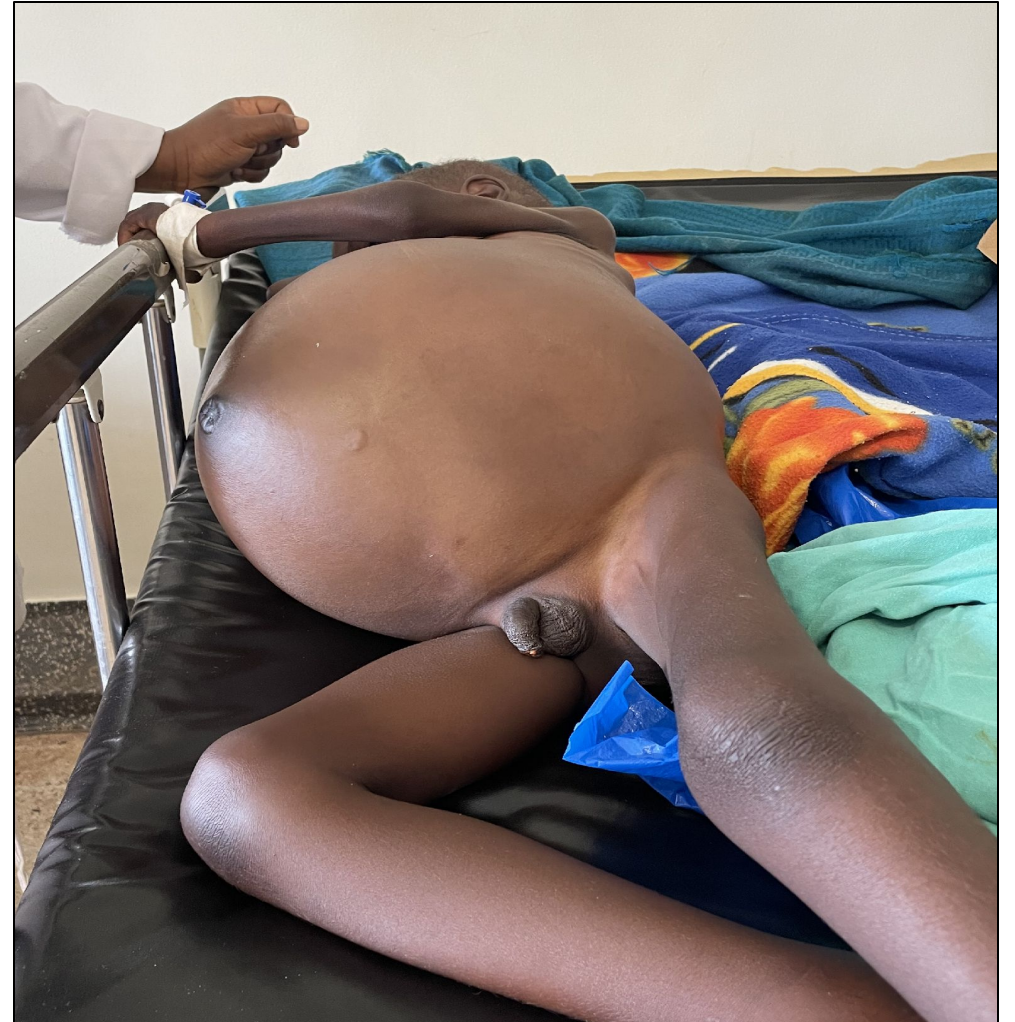
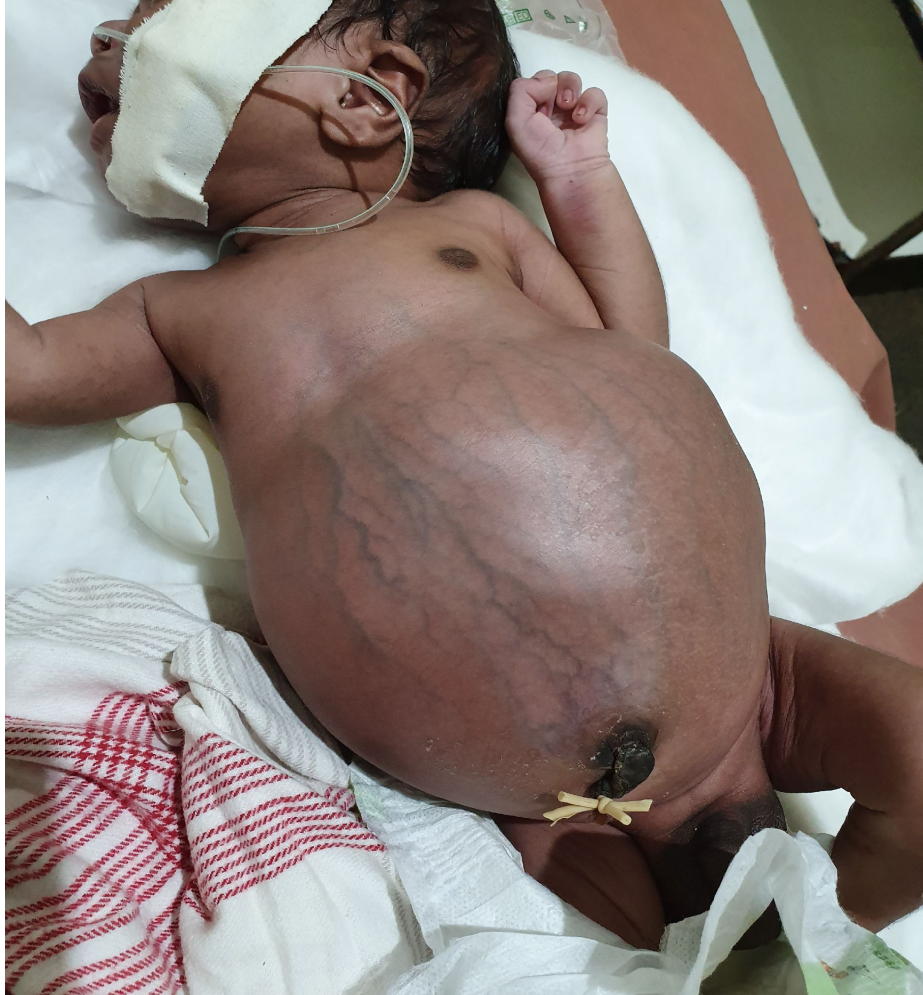
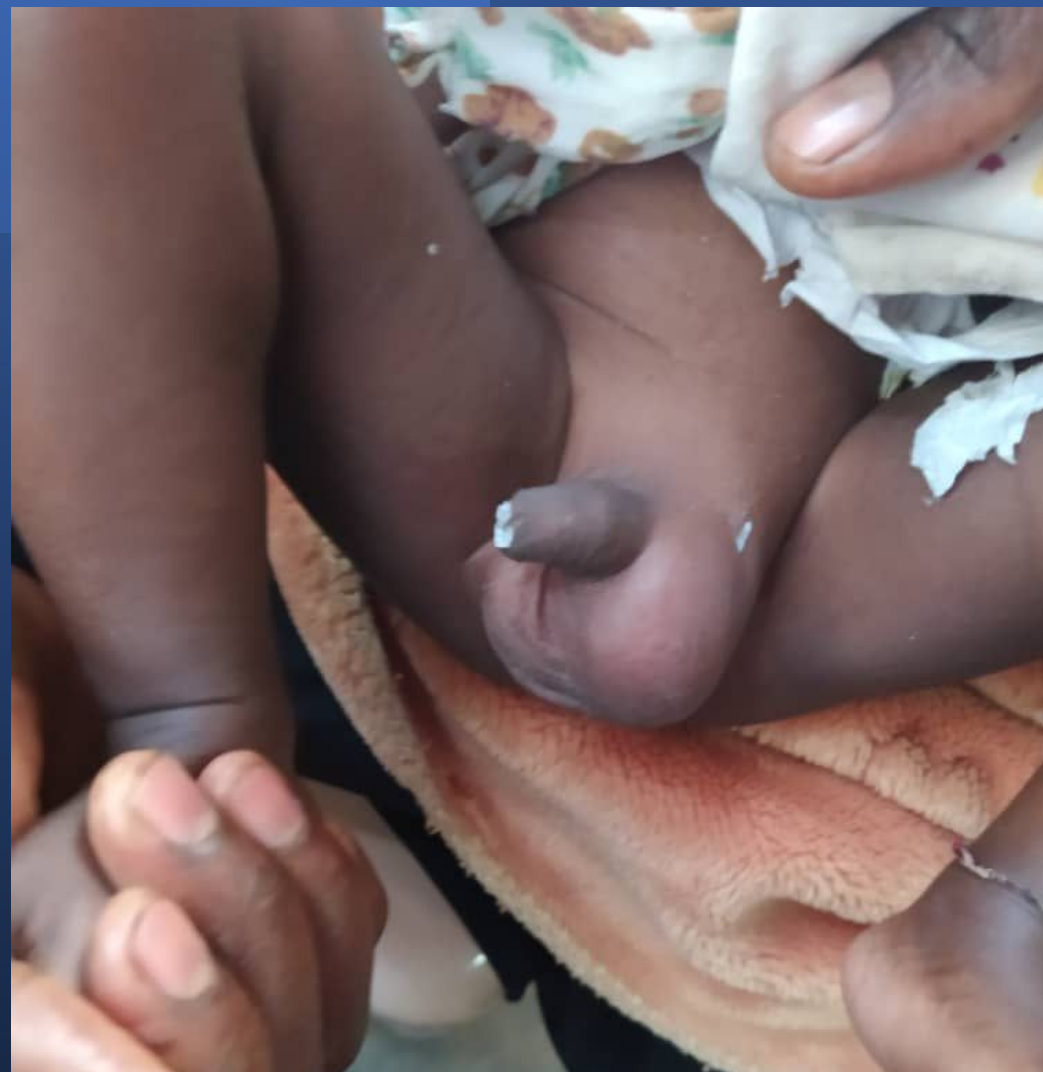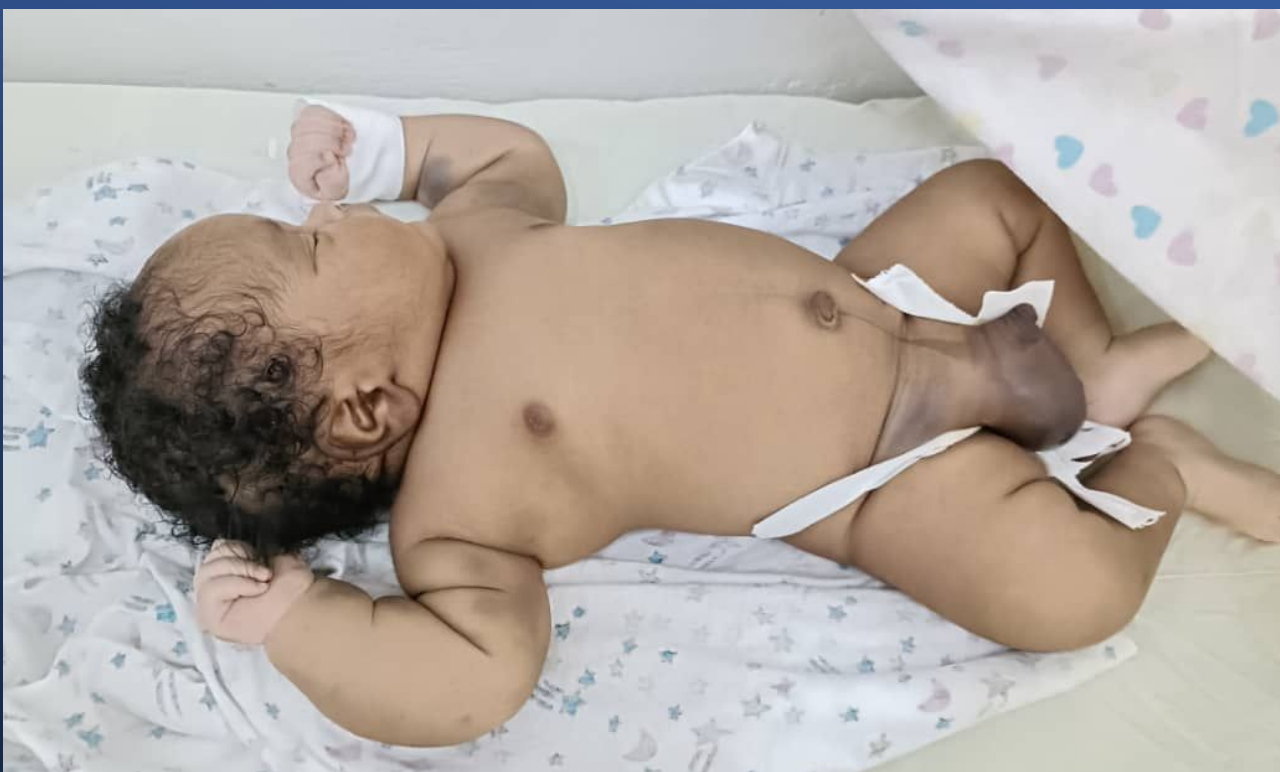Are there any procedures that are useful
as patient awaits to get to theatre?



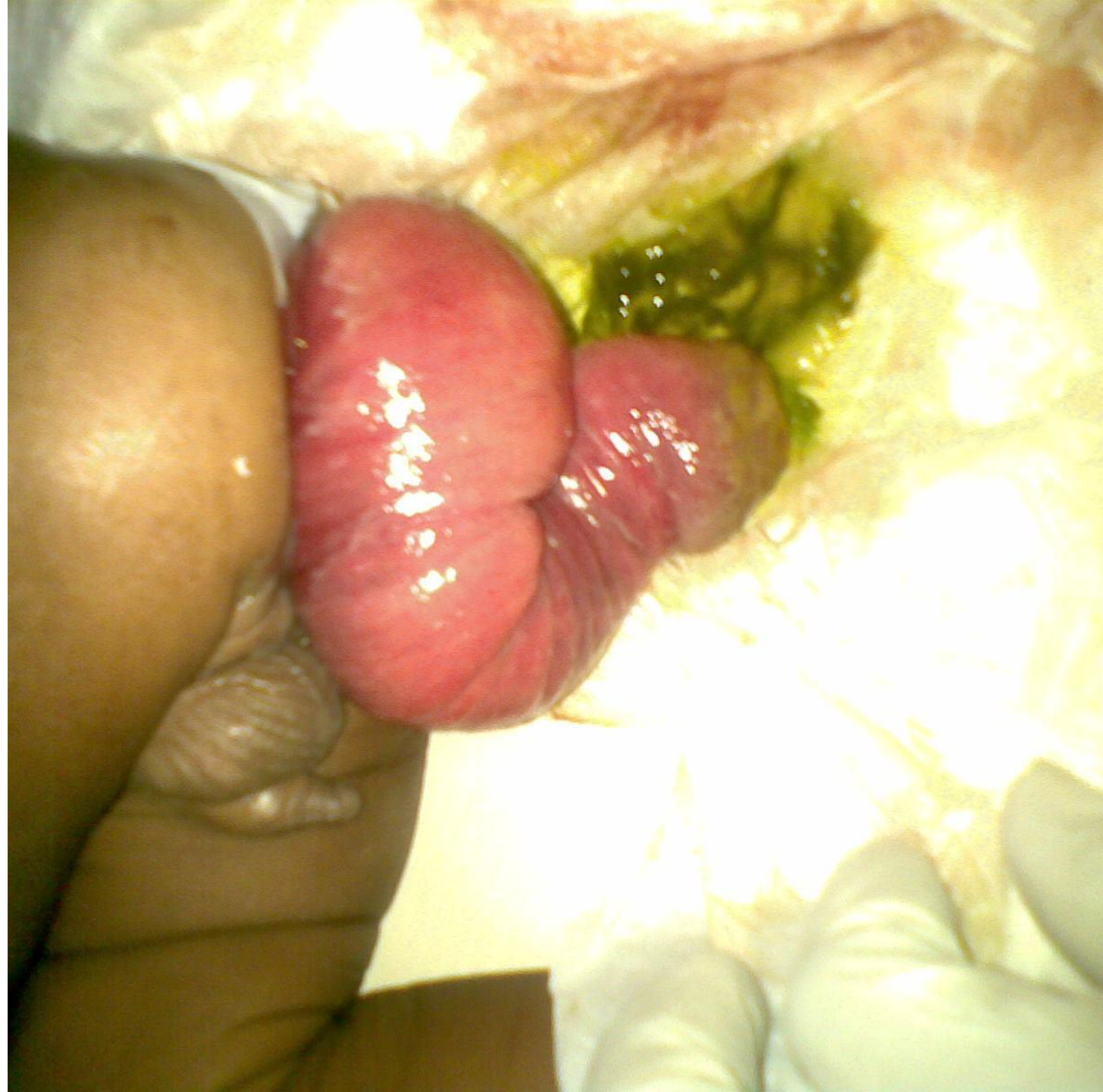peritoneal drainage

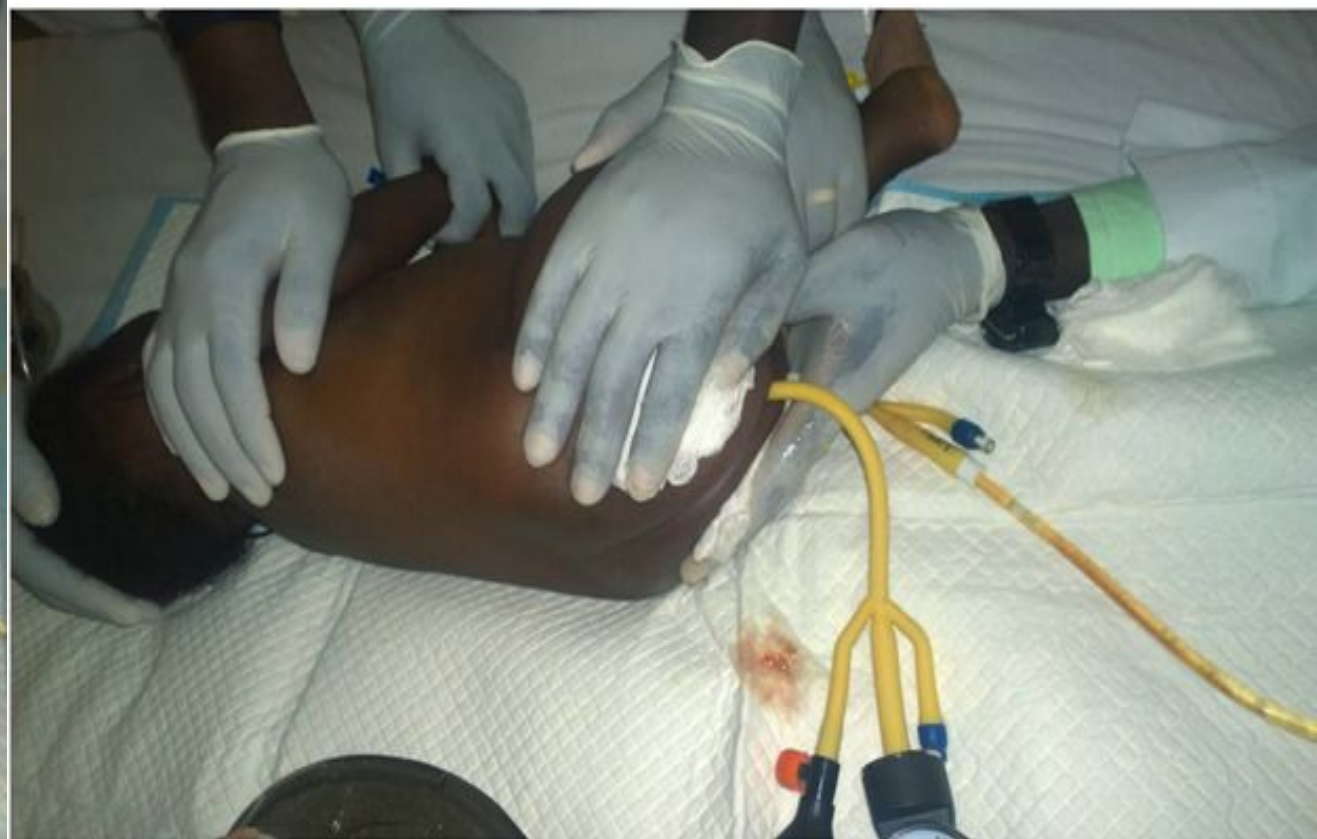
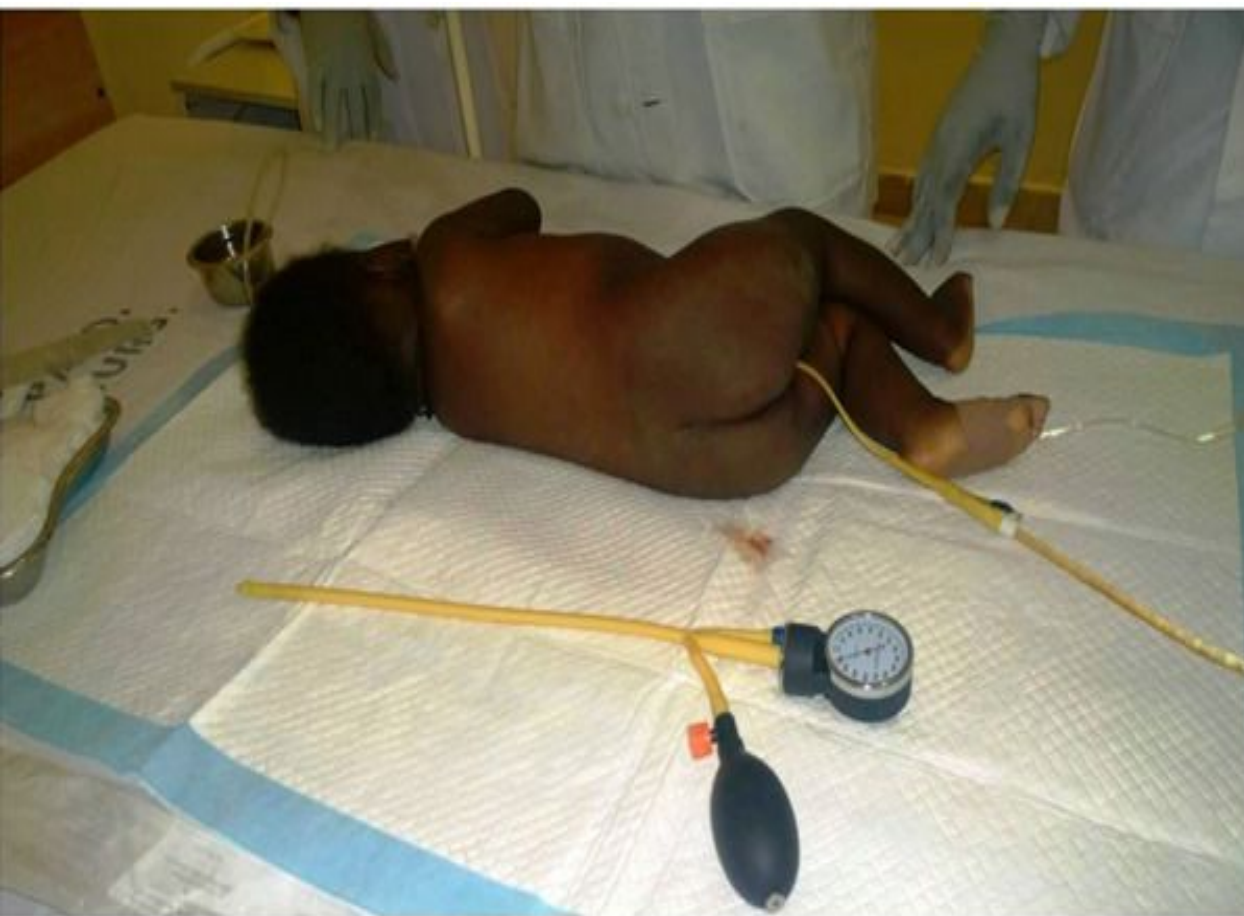


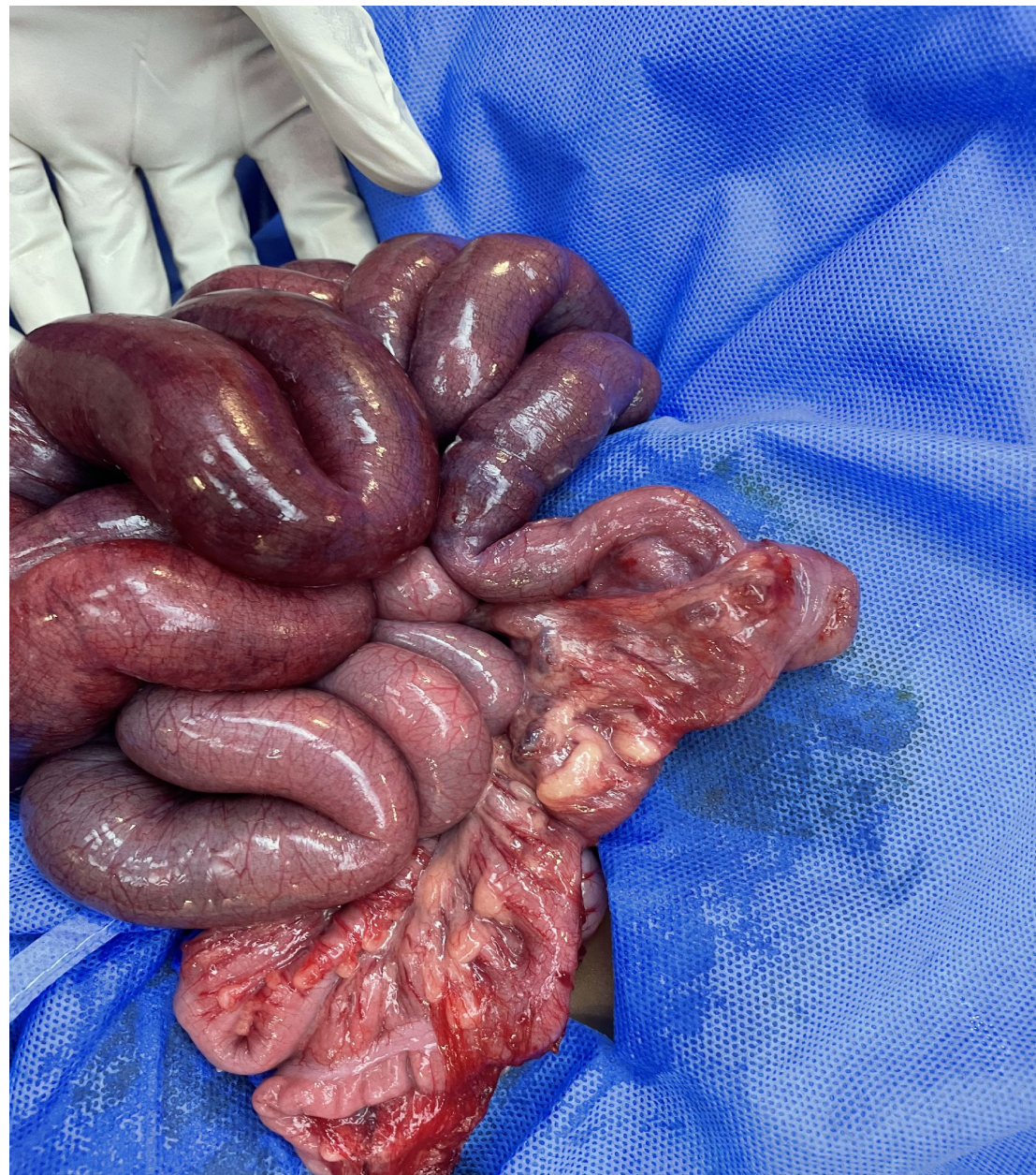
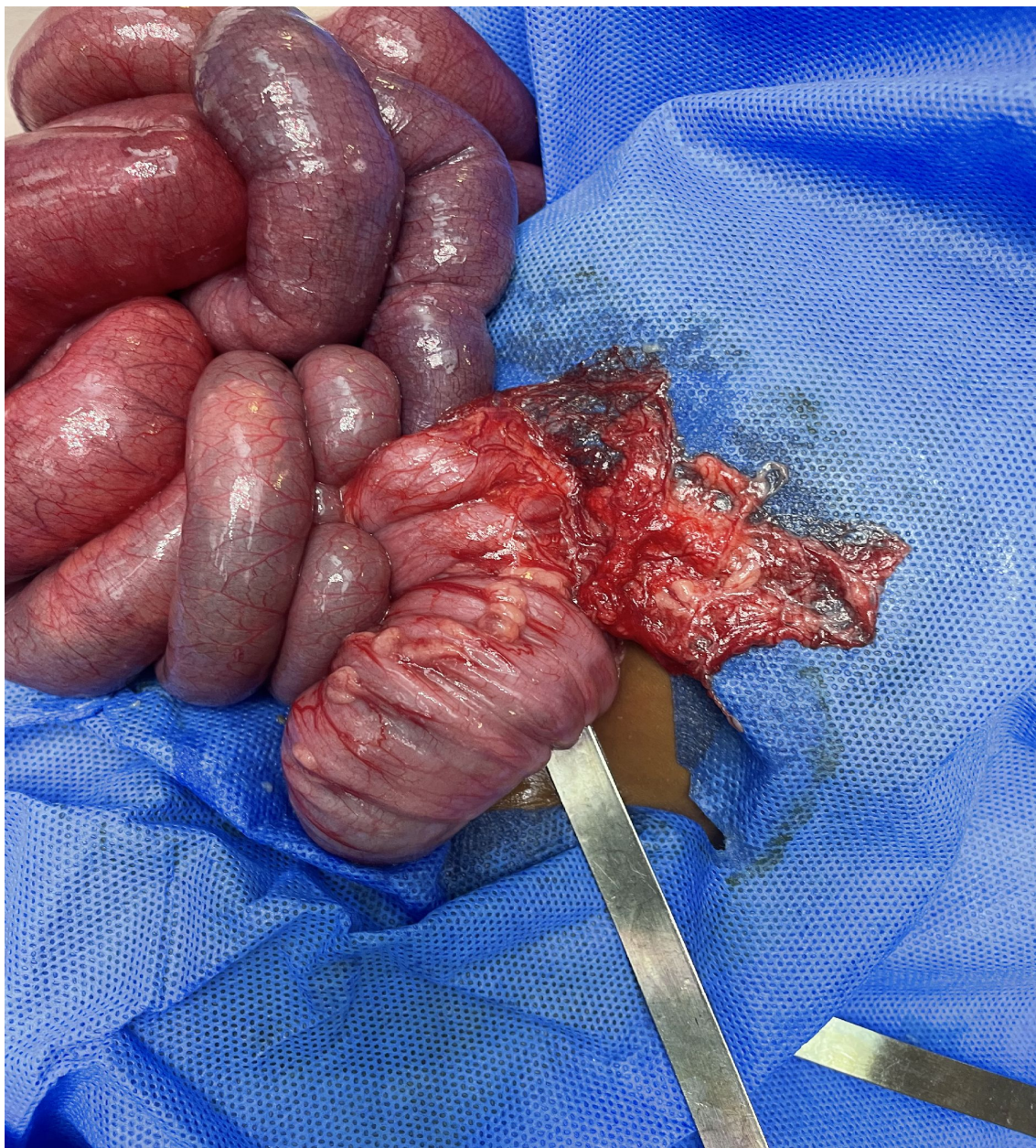
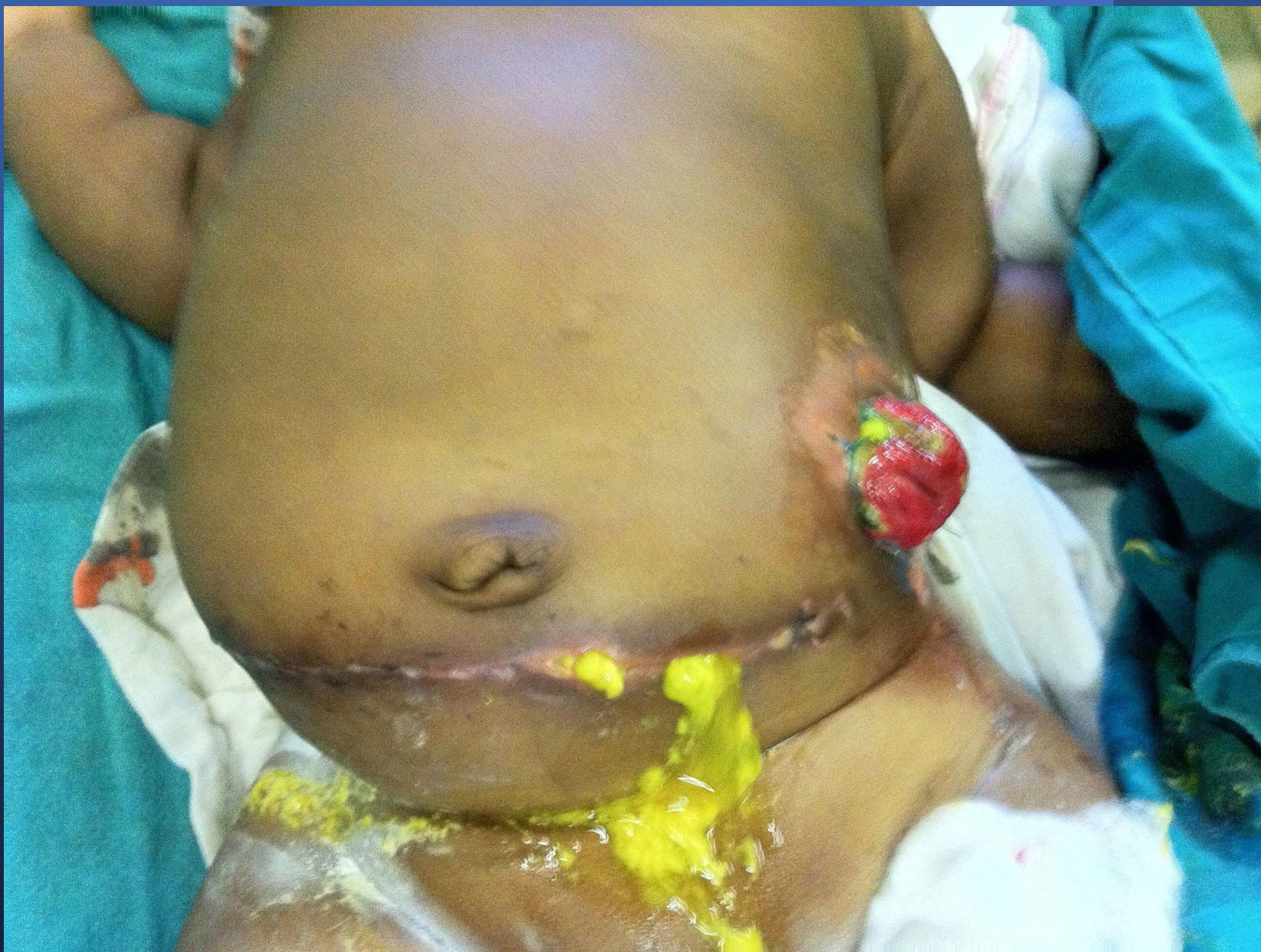Intussusception
OR Rectal
prolapse?

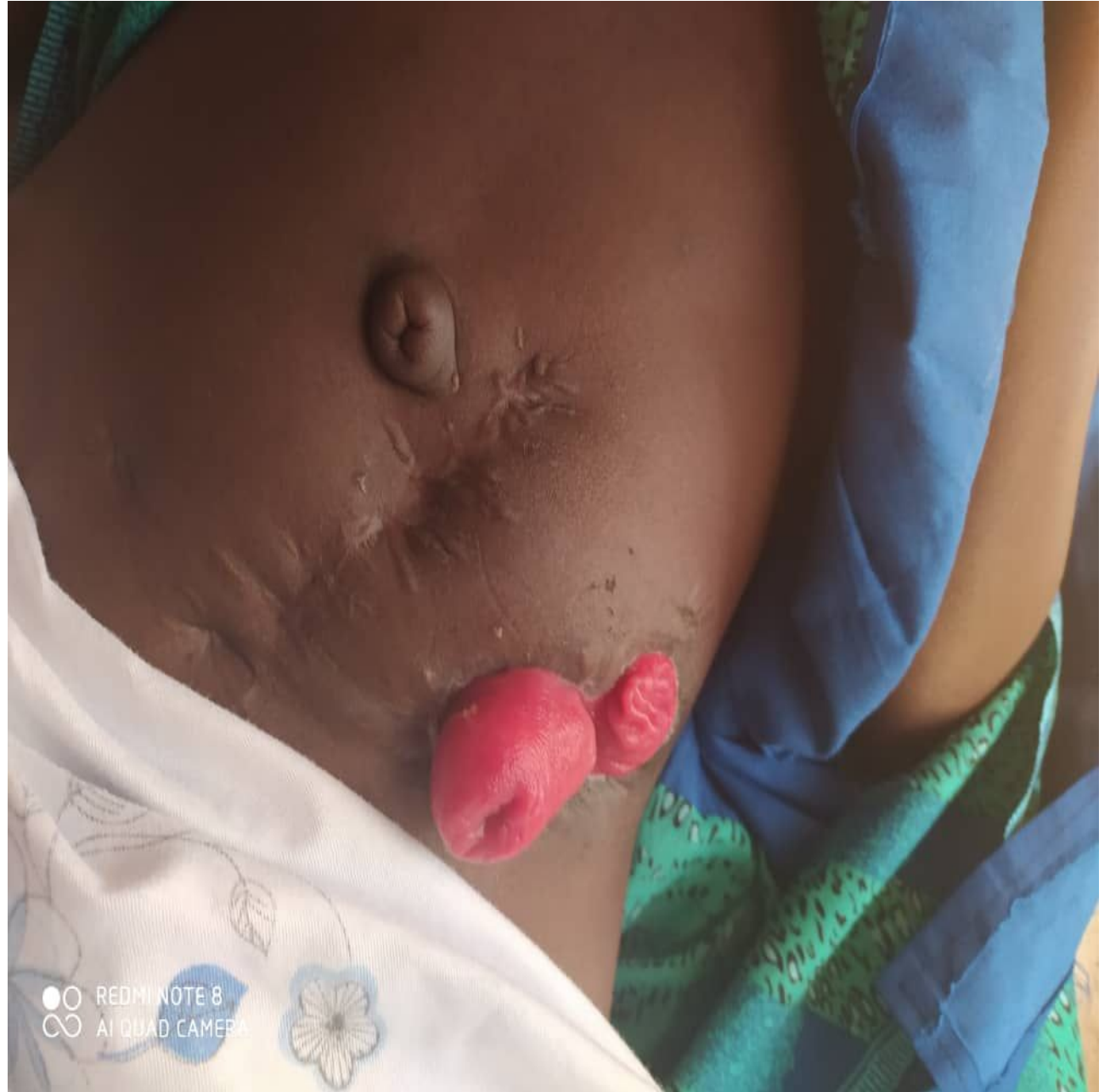
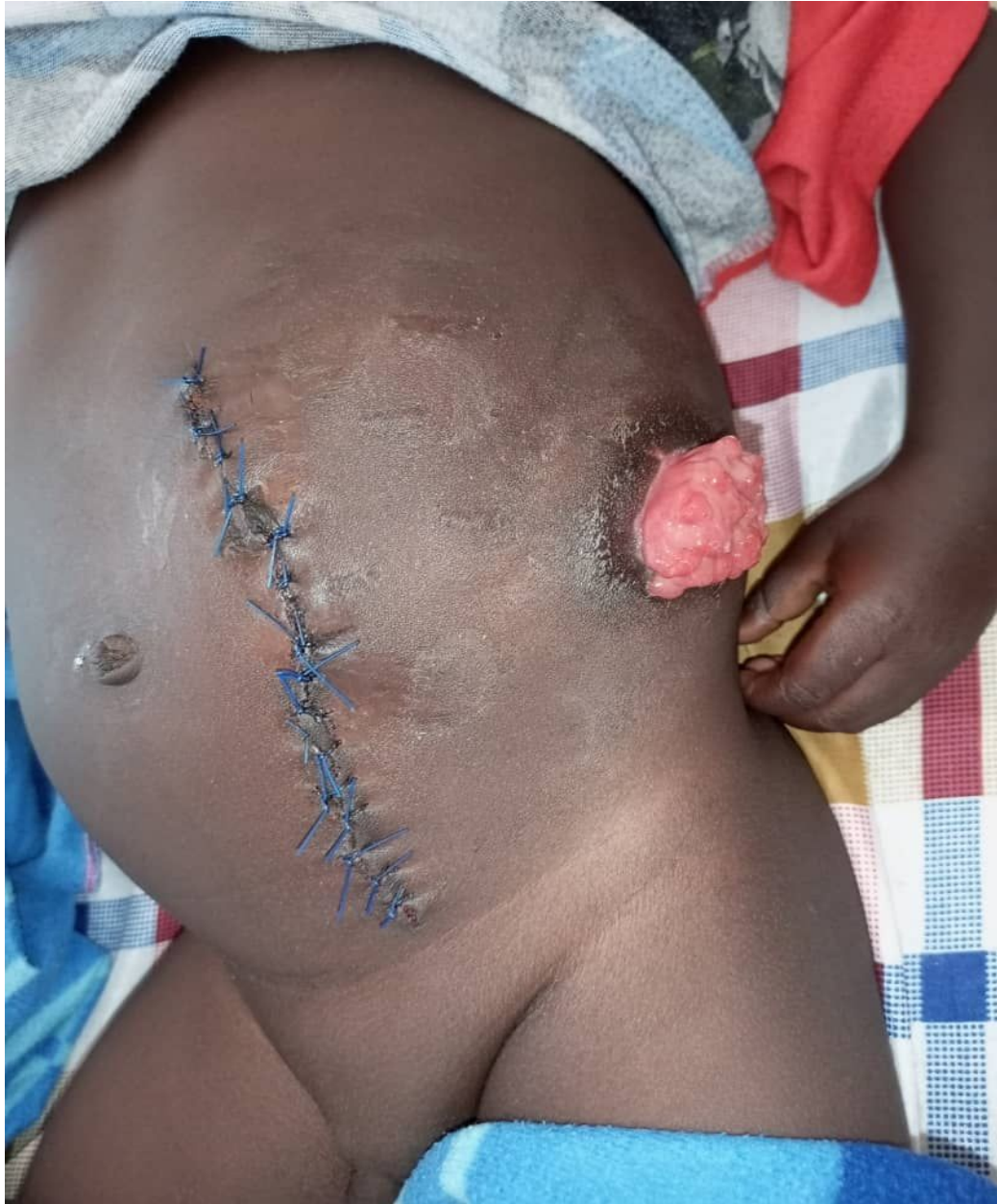
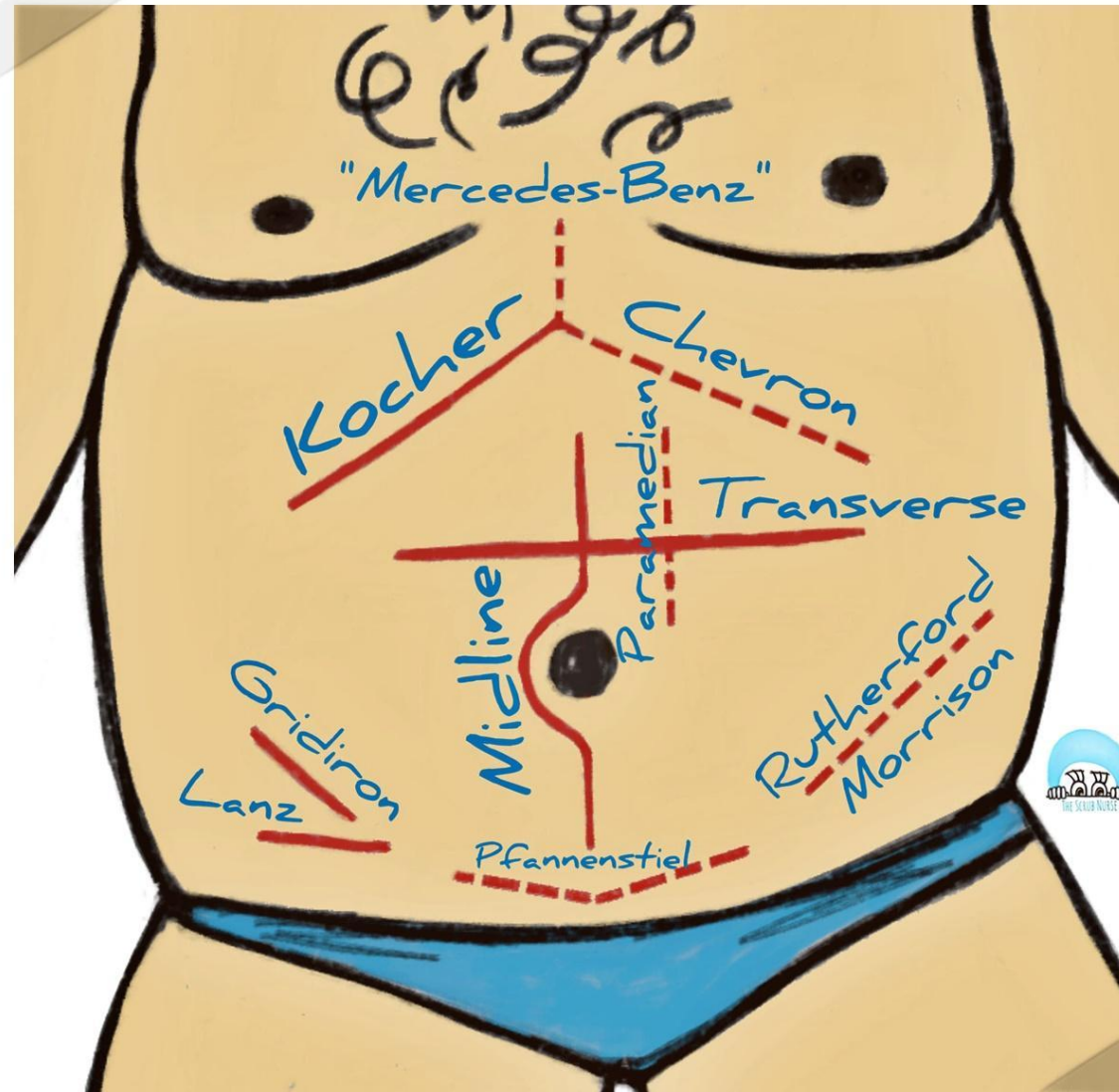












IN CONCLUSION.....

