Clinical Pathological Case (CPC)

Seed
GLOBAL HEALTH

CPC
CASE-BASED LEARNING SERIES
"Mastering Emergency Care"

Disclaimer

Clinical Pathological Case training videos are for educational purposes and should not be used as the sole source of reference during patient care. Always refer to official guidelines and consult qualified professionals before applying any practices

Pre-hospital presentation and hand over

Transfer Details:	Community facility transfer.	Ambulance type C (ALS).	Crew. One EMT and an emergency driver

Equipment and Requirements:

- PPE for the crew
- OPA and NPA for respiratory support.
- Suction device.
- Oxygen cylinder.
- Nasal prongs
- Diagnostics (stethoscope, thermometer, Bp machine).

Hand over

Darius An EMT Dispatched to evacuate and transfer a female 53-years old from home to Kampala International hospital.

Situation: 53/F collapse > LOC > 3 tonic clonic seizures > altered mental status today

Background: hypertension 2 Yrs , 1 week gen. headache, dizziness and blurred vision.

Assessment : Not protecting airway (GCS 10), BP 210/123mmhg, HR 90/min, RR 24 min, O2 90%,on RA, RBS 13mmol/dl, temp 37.0

Recommendations : for possible airway protection ,Further investigations and management.

Management.

Airway was suctioned and supported with OPA.

Oxygen was administered via nasal prongs 5liters and achieved 96%, IV fluid –IV Normal saline 500mls slow

IV paracetamol administered 1gm STAT, IV Diazepam 10mg due to active convulsions and Urinary catheter inserted which collected 900mls on hand-over

ED Arrival

53/F in altered mental status with nasal prongs on 5L of O2 and urinary catheter in place.



Primary Survey

A: noisy breathing, with OPA in situ ,neck is soft

B: Labored breathing. RR-26 breaths/ minute, SP02 - 92 % on O2 ,fine crepitation bilaterally

C: Warm extremities, cap refill 2 sec, Reg. PR 90 b/min , BP:209/120mmHg

D: GCS =8/15 (E=2, V=2, M=4), Pupils 2mm , equal , RBS 13 mmol/L

E: T: 36.5˚C, No pallor. 900mls vol. in urine bag on admission

Poll 1

From the primary survey, what are the eminent emergencies?

ED Intervention

A: Elevated head of bed 30°, suctioning of airway

B: NC >> NRM 10 L .SPO2: 92 >> 98%

C: Cardiac monitor – sinus tachycardia

D: IV phenytoin 1gm START

E: monitoring of temperature

SAMPLE HISTORY

- **Signs & Symptoms:** Headache , blurry vision, dizziness. Seizures, LOC , hypertension and tachypnoea
- **Allergies:** None
- **Medications :**Nifedipine and HCTZ
- **PMH:** HTN for 2 years
- **Last Meal:** 5 Hrs ago
- **Events Leading to Presentation:** hx of collapse , LOC and convulsions.

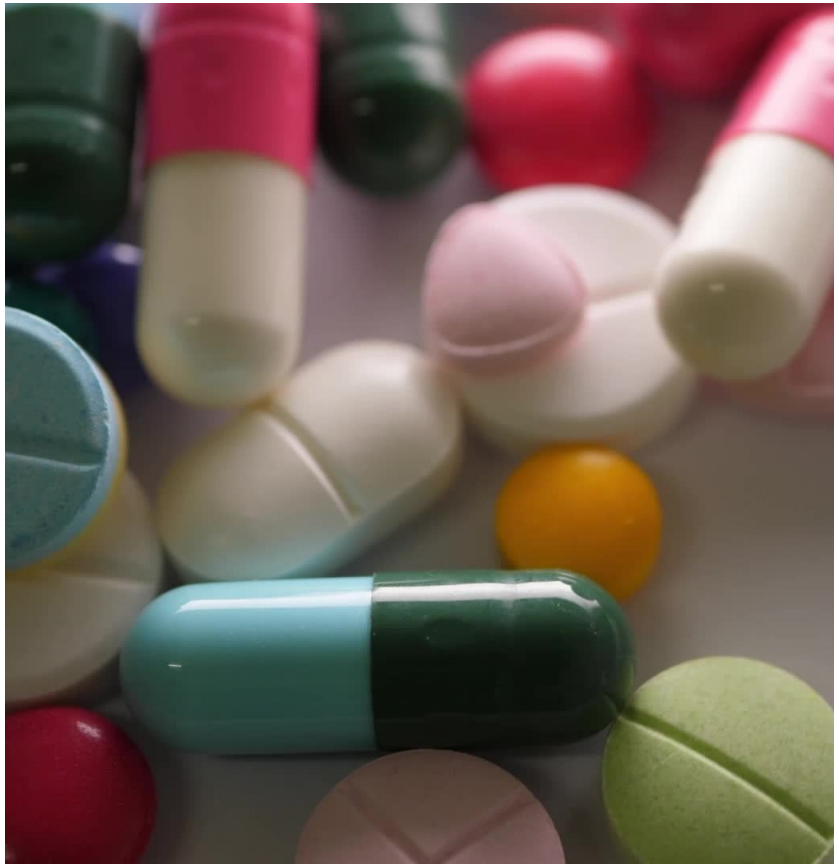

Audience

- Any additional information?



Expert



What are your initial thoughts?



What is you preparation and approach to this patient?

Expert opinion?



Any additional thoughts at this point?



Any additional info you would want to get?



SECONDARY SURVEY

Head And Neck: No pallor, no jaundice ,with JV distension

Chest: lower chest wall indrawing , bilateral fine crepitation

HEART :S1,S2 heard. No murmurs.

P/A: Soft ,nontender , no palpable mass.

Extremities: warm

Neurological: agitated. hypotonia , neck soft

Skin: Intact

Spine: No step offs / no tenderness

Problem list

- Generalized tonic–clonic seizures
- Altered mental status
- Severely elevated BP → hypertensive emergency
- Hypoxia and crepitation on the lung
- Raised intracranial pressure

Poll 2

What are your differential diagnoses for this patient?

Differential diagnoses

Seizures +Altered Mental Status + Severely elevated BP

Differential diagnosis
Intracerebral hemorrhage (pontine bleed)
Cerebral malaria
Intracranial tumor

LABS

TEST		RESULTS	NORMAL RANGES
1.	**Malaria blood slide**	No parasites seen	
4.	**Renal Function tests** Creatinine Urea Potassium sodium	 83.6umol/L 3.56mmol/L 4.4mmol/L 138.4mmol/L	 41-81 2.8-7.2 3.5-5.5 135-150
5.	**Complete blood count** Hb WBC platelets	 14.8 g/dL 8.45 302	 12-16 4-11 150-450

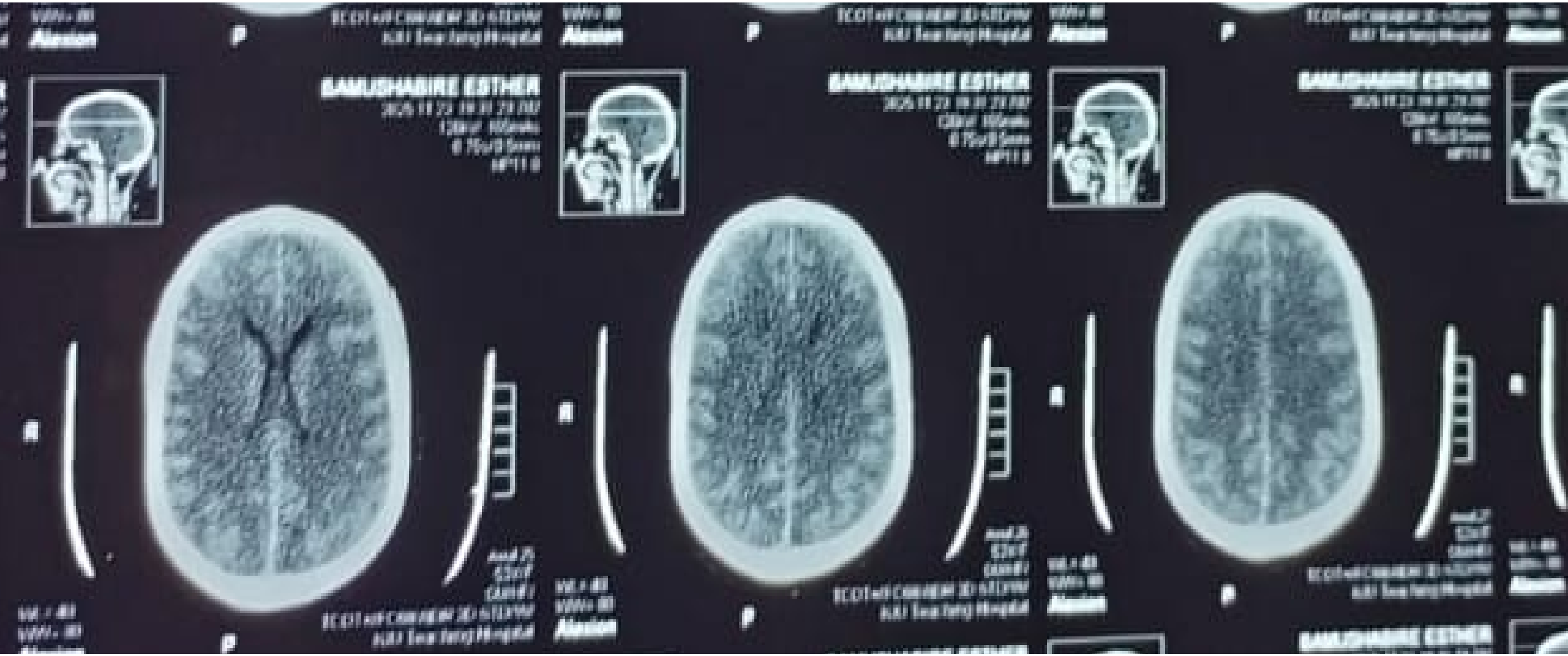
Alexion
BAMIJOHABIRE ESTHER

Poll 3

What are the pathological findings from this CT scan?

Differential diagnoses

Seizures +Altered Mental Status + Severely elevated BP

Differential diagnosis	Exclusion criteria /inclusion
Intracerebral hemorrhage (pontine bleed)	No bleed on CT scan
Cerebral malaria	Negative malaria results
Intracranial tumor	BP may be normal ,gradual and chronic symptoms, focal seizures

Expert opinion



What are your differentials at this point

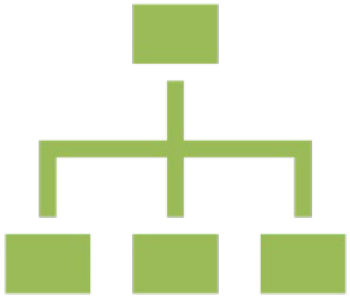

What is your management plan?

Seizures +Altered Mental Status + Seizures +Severely elevated BP

Differential diagnosis	Inclusion/exclusion
Electrolyte imbalance	Normal Potassium and Sodium levels.
Hypertensive encephalopathy	Hypertensive emergency with brain edema on CT scan.
Ischemic Stroke	No infarction on CT scan - Normal CT scan if early ischemic stroke

Working diagnosis

Known Hypertensive patient with Hypertensive encephalopathy with Flash pulmonary edema .

Definitive management plan

- Patient was intubated and mechanical ventilation
- Hypertonic saline 3% over 30 minutes
- Labetalol 20mg iv over 2min then 1-2mg/min infusion .Reduce Mean Arterial Pressure by 20-25% in first hour then lower to 160/100-110 mm/hg over next 2-6 hours
- IV Lasix 40mg
- Phenytoin 250mg iv
- NG-tube for feeding
- Glucose and temperature control

Disposition plan : ICU admission



Expert

Pearls and pitfalls

Elevated blood pressure

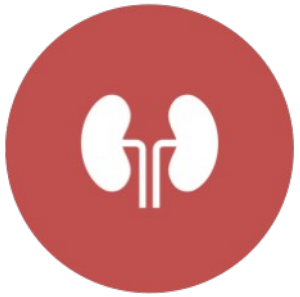

HTN emergency : BP elevated (≥110mmhg diastolic)+ acute target-organ damage – Requires IV therapy



Severely elevated **:** BP elevation (≥110mmhg diastolic) without acute organ damage – can be treated more slowly with oral agents

Hypertensive Encephalopathy.

High BPs → Cerebral vasodilatation → endothelial dysfunction → Blood brain barrier breakdown → **vasogenic oedema (↑** vascular permeability) → ↑ ICP → encephalopathy

It is reversible if treated early.

RECOGNITION OF HTN ENCEPHALOPATHY

CLINICAL FEATURES:

Neurological : headache ,agitation ,confusion , visual disturbance ,vomiting ,seizures , ↓GCS /coma

Fundoscopy : Papilledema , Retinal haemorrhages / exudates

***Investigations :Non-contrast CT brain or Brain MRI ,RFTs , Electrolytes ,Creatinine ,ECG ,Troponin ,Urinalysis ,CXR**

BP REDUCTION TARGETS

- Initial goal (first 1-2 hours)
  MAP –no more than 20-25 %

- Then (next 24hours)
  Gradual reduction toward 160/110mmhg

❖ ***NB: Exception :Aortic dissection > Rapid aggressive reduction***

- Drug choice –IV Sodium nitroprusside , IV Nitroglycerin , IV Labetalol , IV Nicardipine ,***IV Hydralazine(in eclampsia)***

MANAGEMENT

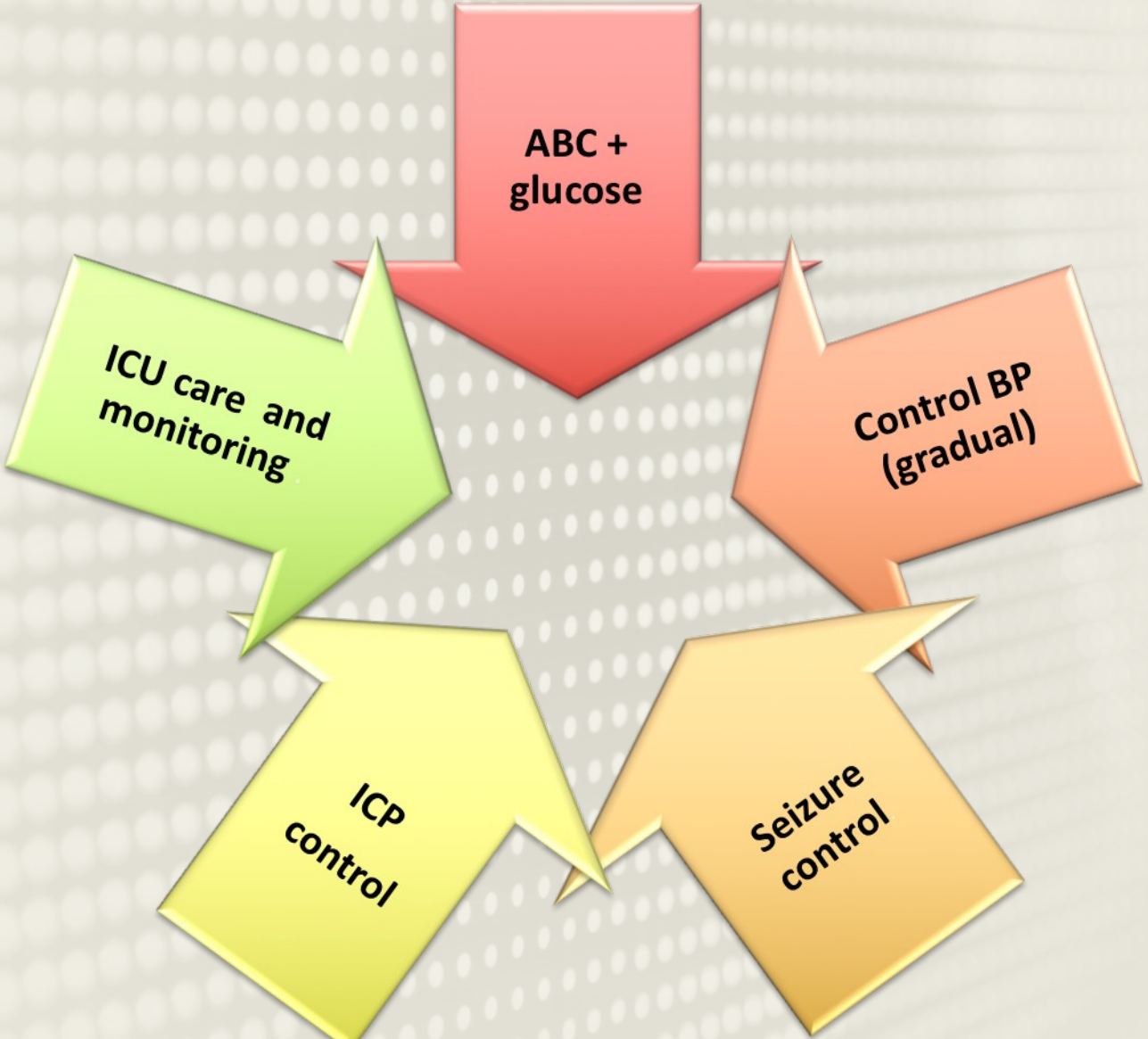
ABC + glucose
ICU care and monitoring
Control BP (gradual)
ICP control
Seizure control

RESOURCES

1.Rosen’s Emergency Medicine

2.Tintinalli’s emergency Medicine

3.BMJ 2024 –Evaluation and management of hypertensive Emergency

4.Medscape /Neurologic Summary 2024

5. https://pubmed.ncbi.nlm.nih.gov/40818477/

6. https://pubmed.ncbi.nlm.nih.gov/10972386/

7. https://www.nejm.org/doi/full/10.1056/NEJM199010253231706

CPC -Case-Based Discussion Wall of Fame

TOPIC	PRESENTER	EXPERT	MODERATOR	MENTOR	DIAGNOSIS
Altered Mental Status	Dr. Jimmy Atyera	Dr. Kenneth Bagonza	Dr. Daniel Olinga		Atrial Fibrillation
I Can't Breathe	Regan Kakande MBChB V	Dr. Doreen Okong	Dr. Anna Kaguna	Dr. Daniel Olinga	Tension Pneumothorax
My Neck is Stuck	Dr. Emmanuel Mbaruk	Dr. Joseph Kalanzi	Dr. Anna Kaguna	Dr. Tracy Walczynski	Tetanus
It keeps dripping	Hennrietta Lunkuse MBChB V	Dr. Ambrose Okello	Dr. Anna Kaguna	Dr. Robert Wangoda	Rectal Polyp
I'm yellowing and can't pee	Doreen Ndagire Sanga MBChB IV	Dr. Linda Nalugya	Dr. Anna Kaguna	Dr. Deo Edemaga	Hepatorenal syndrome
I fell off a boda-boda	Tithi Tripathi, MBCHB IV Jane Nalunkuuma EMT II	Dr. Prisca Kizito	Dr. Danioel Olinga	Dr. Doreen Okong Andrew Okiror	Lung Re-expansion syndrome
Breathless, Yet Breathing Deep	Rebecca Asiimire Winfred Kingfred Wangechi EMT II	Pius Opejo	Dr. Anna Kaguuna		Diabetic Ketoaciodosis
My Body is paining	Maria N. Namujja, MBChB V Melvin Bongozana EMT II	Dr. Joseph Emuron	Dr. Anna Kaguna	Dr. Baturaki Amon	Acute Kidney Injury
I feel them crawling	Patience Kwagala MBChB V Evy Obare, BSc. Paramedical	Dr. Gumisiriza Nolbert	Dr. Jimmy Atyera		Alcohol Withdrawal Syndrome
Baby has a fever	Nyesigamukama Hamson MBChB V Banura Deborah Kirabo	Dr. Jaimini Popet	Dr. Daniel Olinga	Dr. Kaina Vincent	Complex febrile convulsions
She had Multiple Jerky Movements	Katushabe Bridget Ericah MBChB V Kusseewo EMT II	Dr. Aggrey Lubikire Joseph	Dr. Daniel Olinga		Complicated Malaria in Pregnancy
CPC Secretariat: Emmanuel Okumu , Andrew Twineamatsiko, Bonaventure Ahaisibwe , Jimmy Atyera, Daniel Olinga, Anna Kaguna					

Acknowledgements

- DELTA-EM
- MAK-EMIG
- MUST-EMIG
- KIU
- St. Francis Nsmabya Training School
- St. Micheal Lubaga Training School
- ECAU
- Seed Global Health Uganda