Clinical Pathological Case (CPC)

Seed
GLOBAL HEALTH

CPC
CASE-BASED LEARNING SERIES
"Mastering Emergency Care"

Disclaimer

Clinical Pathological Case training videos are for educational purposes and should not be used as the sole source of reference during patient care. Always refer to official guidelines and consult qualified professionals before applying any practices

Case Based Learning Series

"Student Led Adult Learning"

CPC
CASE-BASED LEARNING SERIES
"Mastering clinical Reasoning in Emergency Medicine"

Seed
GLOBAL HEALTH

Clinical Pathologic Case (CPC)

Emergency Medicine Case Based Series



THEME:

I just can't catch my Breath

Date: 30TH JAN 2026 | **Time:** 7:00 PM - 8:00 PM

Expert



Dr. Guloba Umarashid
EM physician lead with Case Hospital Tilenga Project

Case Presenter



Ankit Kalyani
MBChB V
Makerere University

Prehospital Presenter



Nakyanzi Meble
St. Michael Lubaga hospital Training Schools | Yr2S2

zoom

SCAN QR CODE TO REGISTER
https://shorturl.at/ZeGTj

FUMSA

DELTA EM

MAKERERE EMERGENCY MEDICINE INTEREST GROUP

Presenting Complaint

48/m, polytrauma patient being transferred following RTA



Pre-hospital Care Preparation

Patient Presentation:

48y/M managed for polytrauma following a road traffic accident (RTA) from a low-level facility to a high-level facility for advanced trauma management.

- **Transfer details:**

- Inter-facility referral
- Ambulance Type C (ALC)
- Crew: Two EMTs and an emergency driver

- **Equipment and requirements:**

- PPE for crew
- Airway adjuncts
- Suction device
- Oxygen Cylinder
- Non-Rebreather Mask (NRM)
- Splints
- Diagnostics (stethoscope, thermometer, BP machine)
- IV Cannulas
- IV Fluids
- Cervical Collar
- Spine board and accessories

KEY THINGS TO LOOK OUT WHEN PICKING A POLY TRAUMA PATIENT.

Background & Mechanism

- Mechanism of injury, time since injury
- Injuries identified and interventions done
- Stability prior to the transfer

ABCDE Threats

- A: Airway obstruction, reduced GCS, C-spine risk
- B: Respiratory distress, chest tube blockage/dislodgement
- C: Ongoing bleeding, hypotension, shock
- D: Drop in GCS, unequal pupils
- E: Hypothermia, missed injuries, bleeding under dressings

Head-to-Toe Reassessment

- Head/Neck: LOC changes, pupil changes, collar position
- Chest/Abdomen: Breath sounds, chest rise, abdominal distension
- Pelvis/Extremities/Back: Pain, bleeding, deformities, distal pulses

ISBAR Report



Identity: Meble, EMT, dispatched for an interfacility transfer of a 48/M from a low -level facility to a high -level facility.

Situation: 48/m being managed for polytrauma following a RTA.

Background: the patient sustained blunt chest and abdominal trauma with multiple fractures of the right femur, right tibia-fibula, mandible and ribs.

Assessment: airway patent. RR of 21 breaths/min, SpO_2 of 75% on 10L/min via NRM. Heart rate 147 beats/min, CRT <2s, warm peripheries, BP 90/60 mmHg. PEARL. Chest tube in-situ draining blood. Urinary catheter in situ draining yellow urine.

Recommendation: **:** reassessment of the chest tube, chest and lower limb imaging, continuous monitoring of vitals.

Expert



What are your initial thoughts?



What is you preparation and approach to this patient?

Presenting Complaint

48/m, being managed for polytrauma following RTA, developed sudden onset difficulty in breathing and sweating.



Primary Survey

- **Airway:** Patent
- **Breathing:** In respiratory distress, RR-50 breaths/min, SpO_2 - 75% on 10L/min via NRM.
- **Circulation:** warm peripheries, CRT<2s, tachycardia with 147 beats/min.
- **Disability:** PEARL, deformities but no weaknesses, no glucose strip available
- **Exposure :** febrile with a temperature of 38.8 ℃, jaundiced, severe pallor, chest tube in-situ draining blood , SPC in situ draining yellow urine.

What are the possible imminent emergencies in this patient

SAMPLE History

- **Signs & Symptoms:** sudden onset DIB, sweating
- **Allergies:** none
- **Medications:** 2 units PRBCs, tramadol, dynpar, paracetamol, ceftriaxone, clexane, TXA, metronidazole, D50, N/S
- **Past Medical History (PMH):** no history of DM, HTN. Serostatus unknown.
- **Last Meal:** NPO
- **Events Leading to Presentation:** admitted as a referral from Hospital X with polytrauma (blunt chest and abdominal trauma, fractures of mandible, ribs, right femur and right tibia-fibula.



Expert opinion?



Any additional thoughts at this point?



Any additional info you would want to get?

What are the key emergency department management priorities for this patient?

ED INTERVENTION

Airway: Patent

Breathing: started on Oxygen via high flow nasal cannula on 60L/min, FiO2 of 94, SpO2 of 94% achieved.

Circulation: IV fluids (NS-1L), ECG monitoring

Disability: encourage feeding via a straw (yogurt)

Exposure: IV Paracetamol 1g, exposed chest, cleaned chest tube site, redressed chest tube insertion site, IV Ornidazole 500mg, ceftriaxone 2g.



Secondary survey

- **HEAD AND NECK:** laceration of the head, bandaged
- **CHEST:**

Inspection: chest moving with respiration with a respiratory rate of 30 breaths/min, chest tube in situ, hypertrophic scars noted near the angle of Louis

***Palpation*:** mild tenderness noted, no subcutaneous emphysema noted

***Percussion*:** stony dull note on the right side of the chest. Resonant note on the left side.

***Auscultation*:** reduced air entry noted on the right side. Vesicular sounds noted on the left.

- **ABDOMEN:** no scars or lacerations noted.
- **EXTREMITIES:** fractures over the right leg, splinter in situ.
- **NEUROLOGICAL:** GCS 15/15, PEARL
- **SKIN:** warm, pale with lacerations over the upper limbs and head.

What are your differential diagnoses?

Expert opinion



What are your differentials at this point



What is your management plan?

Differential Diagnoses

Diffrential Diagnoses	Reasons
Acute Respiratory Distress Syndrome (ARDS)	Tachypnea, rapidly falling oxygen levels, sweating, chest trauma.
Pulmonary Embolism	Polytrauma, tachypnea, non ambulant patient, DIB
Pulmonary Contusion	Blunt chest trauma, falling oxygen levels, chest tenderness
Hemothorax	Tachypnea, dull percussion note with reduced breath sounds in the right side
Sepsis	Hx of polytrauma, febrile.

Labs

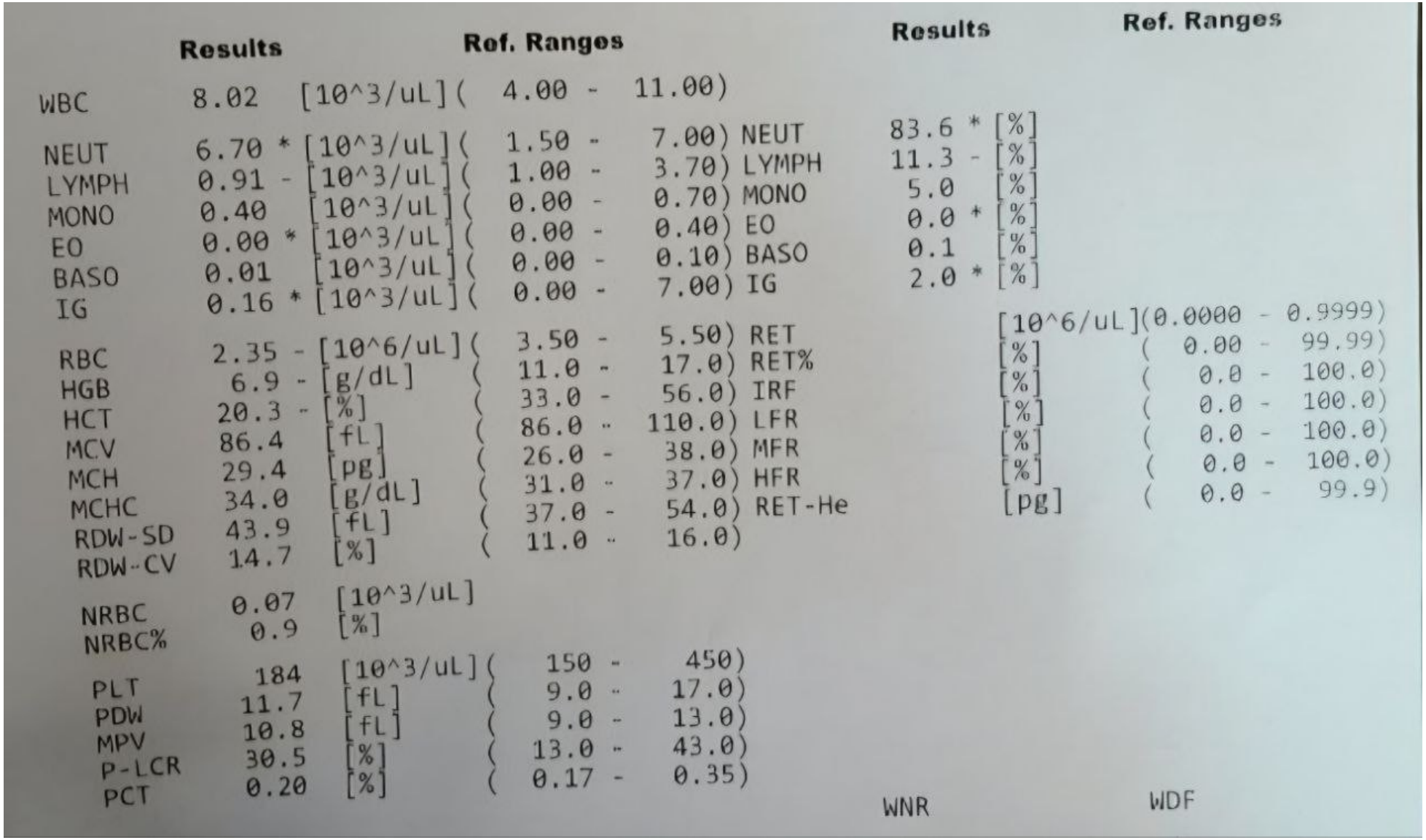

	Results		Ref. Ranges			Results		Ref. Ranges	
WBC	8.02	[10^3/uL]	(4.00 - 11.00)						
NEUT	6.70 *	[10^3/uL]	(1.50 - 7.00)	NEUT		83.6 *	[%]		
LYMPH	0.91 -	[10^3/uL]	(1.00 - 3.70)	LYMPH		11.3 -	[%]		
MONO	0.40	[10^3/uL]	(0.00 - 0.70)	MONO		5.0	[%]		
EO	0.00 *	[10^3/uL]	(0.00 - 0.40)	EO		0.0 *	[%]		
BASO	0.01	[10^3/uL]	(0.00 - 0.10)	BASO		0.1	[%]		
IG	0.16 *	[10^3/uL]	(0.00 - 7.00)	IG		2.0 *	[%]		
RBC	2.35 -	[10^6/uL]	(3.50 - 5.50)	RET			[10^6/uL]	(0.0000 - 0.9999)	
HGB	6.9 -	[g/dL]	(11.0 - 17.0)	RET%			[%]	(0.00 - 99.99)	
HCT	20.3 -	[%]	(33.0 - 56.0)	IRF			[%]	(0.0 - 100.0)	
MCV	86.4	[fL]	(86.0 - 110.0)	LFR			[%]	(0.0 - 100.0)	
MCH	29.4	[pg]	(26.0 - 38.0)	MFR			[%]	(0.0 - 100.0)	
MCHC	34.0	[g/dL]	(31.0 - 37.0)	HFR			[%]	(0.0 - 100.0)	
RDW-SD	43.9	[fL]	(37.0 - 54.0)	RET-He			[pg]	(0.0 - 99.9)	
RDW-CV	14.7	[%]	(11.0 - 16.0)						
NRBC	0.07	[10^3/uL]							
NRBC%	0.9	[%]							
PLT	184	[10^3/uL]	(150 - 450)						
PDW	11.7	[fL]	(9.0 - 17.0)						
MPV	10.8	[fL]	(9.0 - 13.0)						
P-LCR	30.5	[%]	(13.0 - 43.0)						
PCT	0.20	[%]	(0.17 - 0.35)						

WNR WDF

Test	Result		Unit	Ref. Range
LFT				
Serum Total Bilirubin	188.1	H	umol/L	Up To 23.0
Serum Direct Bilirubin	141.9	H	umol/L	Up To 5.1
Serum Alk. Phosphatase	219		U/L	99 - 275
Serum GGT	627	H	U/L	Up To 55
Serum Protein Total	48	L	g/L	66 - 87
Serum Albumin	25	L	g/L	38 - 52
RFT				
Urea	7.5	H	mmol / L	2.7 - 6.4
Serum Creatinine	82		umol/L	44 - 114
Chloride - Serum	106		mmol/l	90 - 110
Serum Sodium (Na)	150		mmol / l	138 - 150
Serum Potassium (K+)	4.6		mmol /L	3.7 - 5.4

Comments

NOTE: Reagents are out of stock for the missing parameters.

End of Report

Labs and imaging

- AP Chest X- Ray (right), showing a possible hemopneumothorax, multiple rib fractures and lung collapse.
- Right leg X-ray (below), showing fracture of distal aspect of femur and communited fracture of the tibia.





What are the pathologies on the radiograph (chest x-ray)

Labs and imaging

- Pelvic X-ray (below), showing fractures at the pubic symphysis and pubic arch.
- Non contrasted Head CT (right), showing dislocation of mandible.





Chest X-Ray with Chest Tube In situ

AP Chest X-ray taken post insertion of chest tube by CTS team to confirm position of chest tube.



WORKING DIAGNOSIS: ARDS SECONDARY TO POLYTRAUMA

ED course

- **Airway:** planned for tracheostomy, ENT team was however, reluctant, continued on high flow nasal cannula at 60L/min, FiO2 of 94.
- **Breathing:** repeat CXR, repeat Lung ultrasound/eFAST, continue high flow nasal cannula.
- **Circulation:** transfuse with PRBCs, ECG monitoring, Maintain IV fluids, IV furosemide 80mg.
- **Disability:** consult orthopedic and neurosurgery, regular bed turning, NGT for feeding.
- **Exposure:** continue Paracetamol, IV antibiotics. Do blood cultures.

Expert

Pearls and pitfalls

ACUTE RESPIRATORY DISTRESS SYNDROME

- Adult respiratory distress syndrome (ARDS) is a severe, life-threatening pulmonary condition that can arise after polytrauma and long bone fractures leading to acute lung injury and progressive respiratory distress, refractory hypoxemia and pulmonary edema.
- **TRAUMATIC CAUSES:**

- Pulmonary Contusion
- Chest Trauma
- Fat Embolism
- Transfusion Related to Acute Lung Injury (TRALI)
- Haemorrhagic Shock
- Multiple Long Bone Fractures
- Burns
- Aspirations related to trauma/ altered consciousness

PATHOPHYSIOLOGY

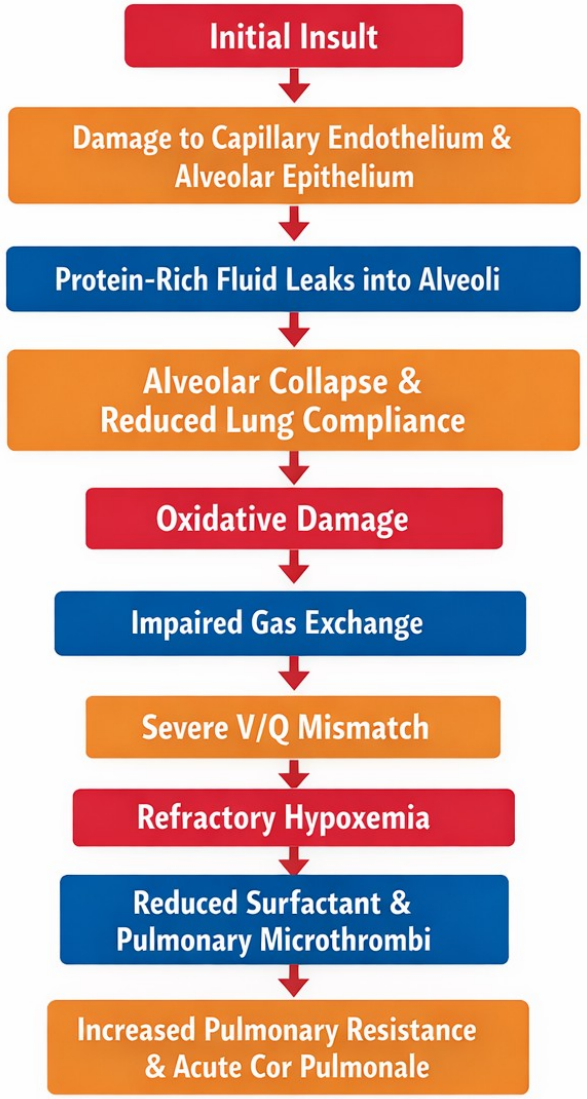

SIGNS AND SYMPTOMS

- Shortness of breath
- Cyanosis
- Fatigue, Cough, Fever, Confusion
- Symptoms may present between 24h to 7 days post insult

TREATMENT

Nonoperative:

- PEEP ventilation and steroids
- treat the underlying pathology/disease

Operative:

- early stabilisation of long bone fractures (femur)
- Prevention
- closely monitor PEEP in patients at risk of ARDS
- Serial X-rays of concerning patients can assist in early identification and intervention

➢ ***Carries a poor prognosis, with a 50% mortality, even when managed in the ICU***